

# IMAGES

## in PAEDIATRIC CARDIOLOGY

Muratori D<sup>1</sup>, Meani P<sup>2</sup>, Quattrocchi G<sup>1</sup>, Pedrotti P<sup>1</sup>. Association of unicuspid unicommissural aortic valve and complex congenital heart disease depicted by cardiac magnetic resonance.. *Images Paediatr Cardiol* 2016;16(3):5-8.

<sup>1</sup>Cardiac Magnetic Resonance Laboratory, De Gasperis Cardio Center, Niguarda Hospital, Milano, Italy.

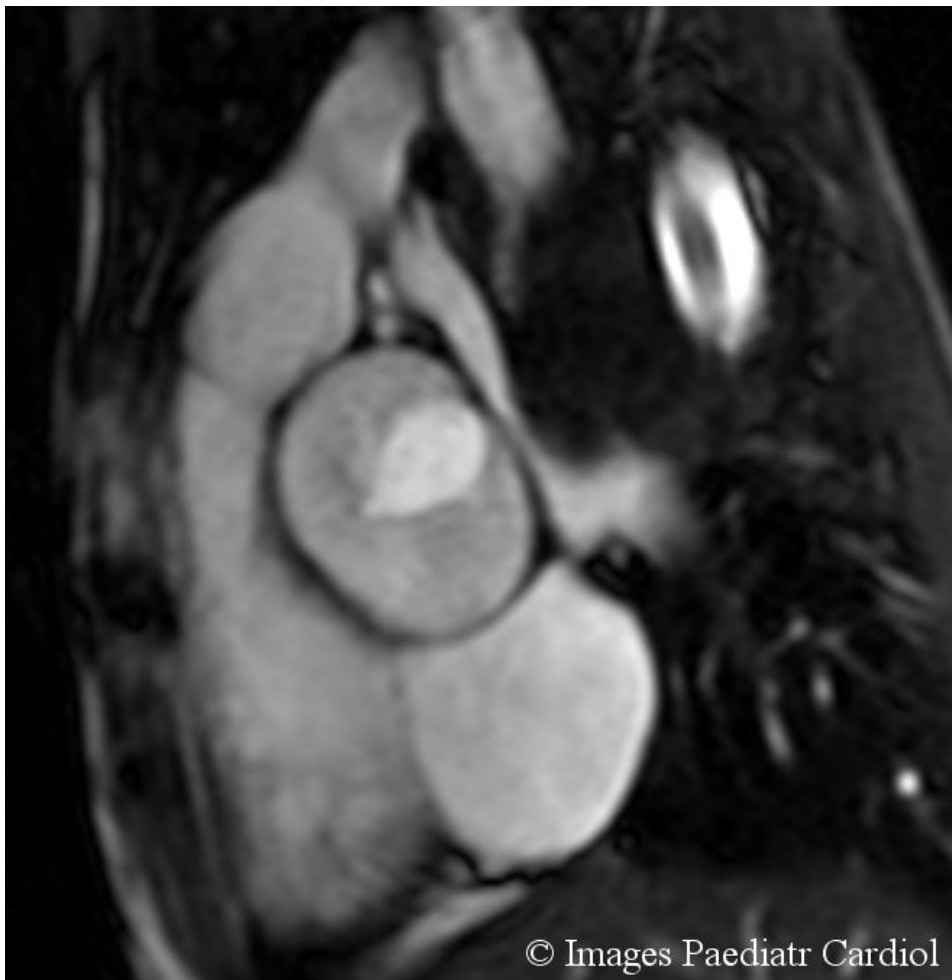<sup>2</sup>Health Science Department, Bicocca University, Milano, Italy.

### Patient

A 12-year-old male child was referred for follow-up cardiac magnetic resonance (CMR) of complex congenital heart disease, characterized by aortic decoarctation, interventricular and interatrial septal defects (VSD and ASD) closure and bicuspid aortic valve.

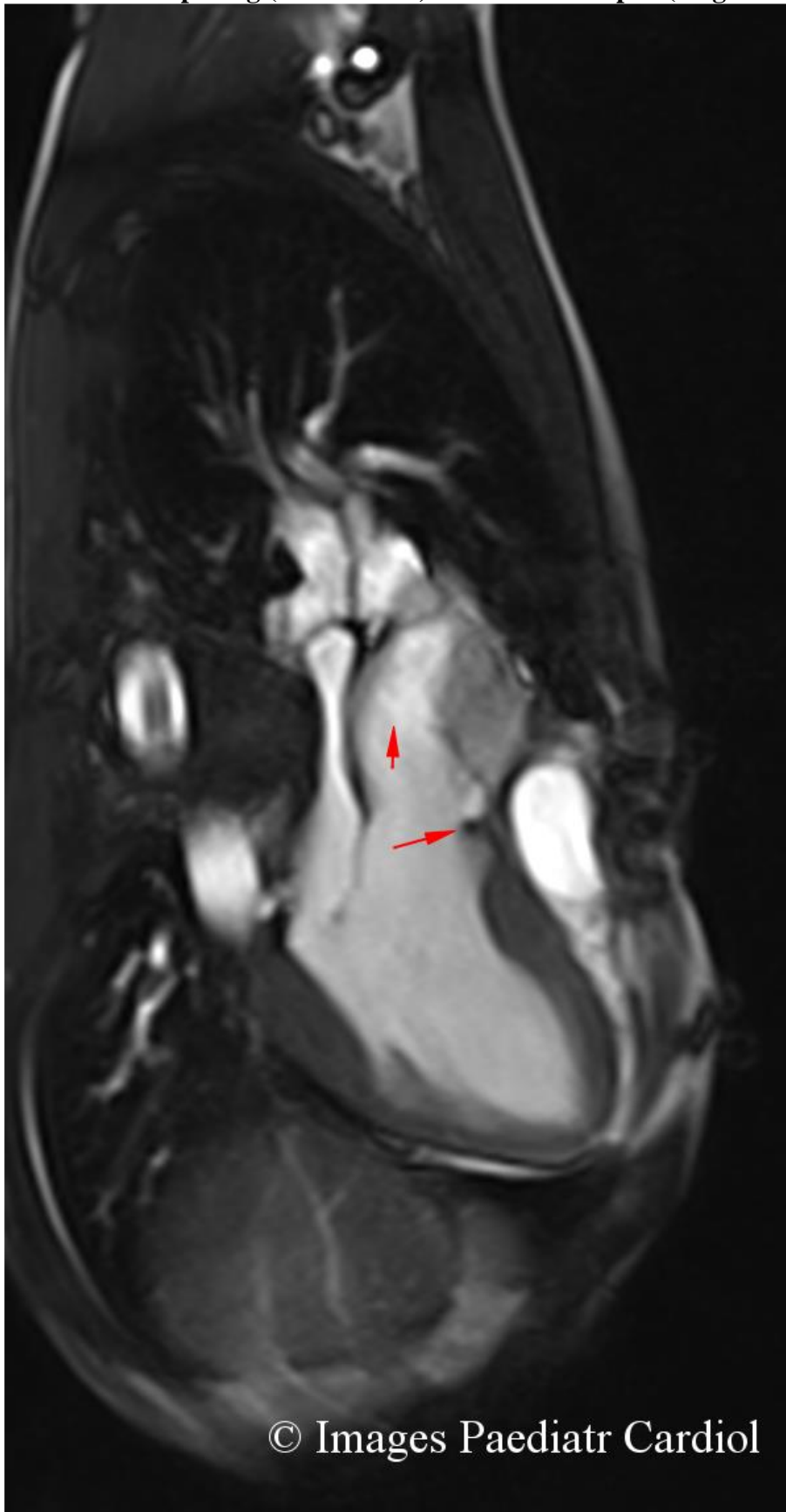CMR showed unicuspid unicommissural aortic valve with normal valve area and without significant regurgitation. A sub-aortic spur was detected, without outflow obstruction. There were no signs of recoarctation nor residual septal defects; both ventricles were of normal size and function (figures 1-3).

**Figure 1. Aortic valve, CMR cine image, systolic still frame, showing unicuspid unicommissural aortic valve.**



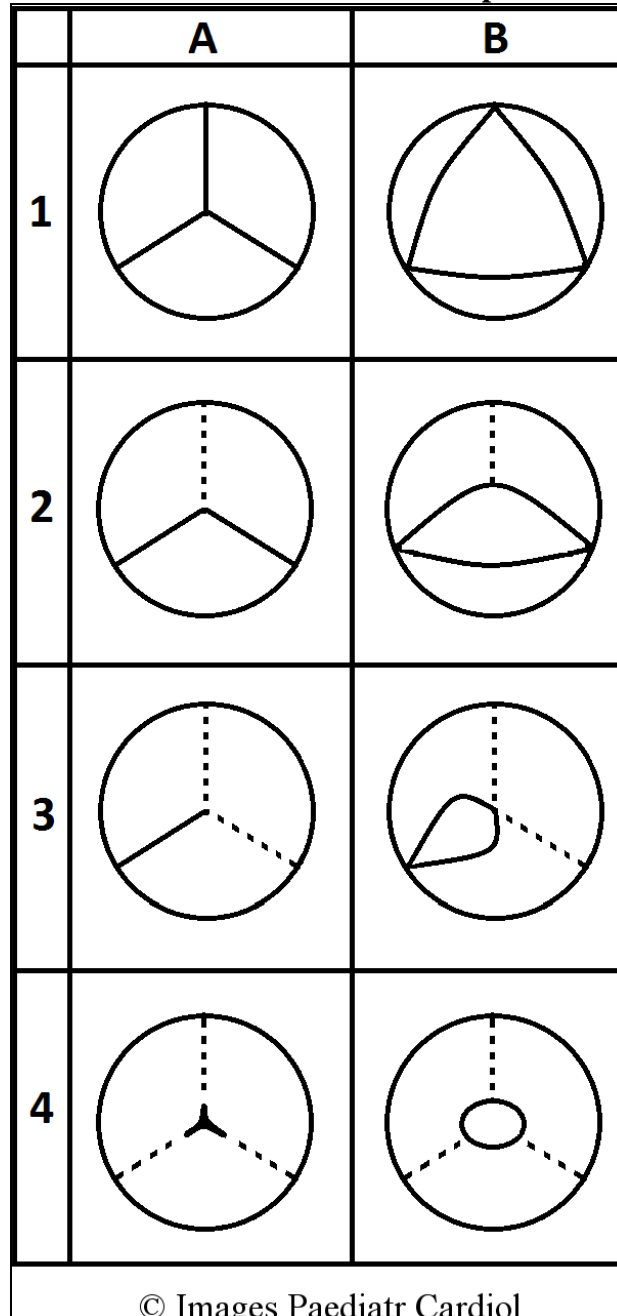
© Images Paediatr Cardiol

**Figure 2. Left ventricular outflow tract, CMR cine image, systolic still frame, showing eccentric aortic opening (short arrow) and subaortic spur (long arrow).**



© Images Paediatr Cardiol

**Figure 3. Schematic illustration of the anatomic variations of aortic valve. (A) closed valve; (B) open valve. 1) Normal tricuspid aortic valve. 2) Bicuspid aortic valve. 3) Unicuspid unicommissural aortic valve. 4) Unicuspid aocommissural aortic valve. Dotted lines indicate the location of commissure in normal tricuspid aortic valve.**



### Discussion

Unicuspid aortic valve (UAV) is a rare congenital anomaly with an incidence of 0.02% in the adult population as estimated by echocardiography.<sup>1</sup> It is usually associated with aortic stenosis or regurgitation.

Two forms of UAV have been described: unicuspid unicommissural aortic valve, in case of presence of a lateral attachment to the aorta and unicuspid aocommissural aortic valve, in case of absence of this attachment.<sup>2</sup>

Transthoracic and transesophageal echocardiography (TTE and TEE) are the gold standard imaging diagnostic techniques for the assessment of aortic valve abnormalities.<sup>3</sup> However, in a recent

*Muratori D, Meani P, Quattrocchi G, Pedrotti P. Association of unicuspid unicommissural aortic valve and complex congenital heart disease depicted by cardiac magnetic resonance.. Images Paediatr Cardiol 2016;18(3):5-8.*

Canadian study on 42 patients who underwent aortic valve surgery for stenosis or regurgitation, UAV had been identified by pre-operative TEE only in 69% of the cases.<sup>4</sup>

CMR has become pivotal in the clinical evaluation of aortic diseases, especially in the context of congenital heart disease.<sup>3</sup> Only a few cases of UAV with coexisting cardiac anomalies detected by echocardiography and CMR have been reported.<sup>1-5</sup>

In our patient, pre-operative echocardiographic assessment had not identified UAV. Moreover, to the best of our knowledge, the combination of UAV, aortic coarctation, and VSD and ASD has not been previously described. CMR allowed the identification of UAV, together with follow up evaluation of complex congenital heart disease, confirming the importance of this diagnostic tool in this clinical setting.

## References

1. Novaro GM, Mishra M, Griffin BP. Incidence and echocardiographic features of congenital unicuspid aortic valve in an adult population. *J Heart Valve Dis* 2003;12:674–8.
2. Anderson RH. Understanding the structure of the unicuspid and unicommissural aortic valve. *J Heart Valve Dis* 2003;12:670–3.
3. Debl K, Djavidani B, Buchner S, Poschenrieder F, Heinicke N, Schmid C et al. Unicuspid aortic valve disease: a magnetic resonance imaging study. *Rofo* 2008;180:983-7.
4. Noly PE, Basmadjian L, Bouhout I, Viet Le VH, Poirier N, El-Hamamsy I. New insights into unicuspid aortic valve disease in adults: not just a subtype of bicuspid aortic valves, *Can J Cardiol*. 2016;32:110-6.
5. Dursun M, Yilmaz S, Sayin OA, Ugurlucan M, Ucar A, Yekeler E et al. Combination of unicuspid aortic valve, aortic coarctation, and aberrant right subclavian artery in a child: MR imaging and CTA findings. *Cardiovasc Intervent Radiol*. 2007;30:547-9.

## Contact Information

© Images in  
Paediatric Cardiology  
(1999-2016)

Davide Muratori  
Cardiac Magnetic Resonance Unit  
Department of Cardiology and  
Cardiovascular Surgery  
Niguarda Hospital  
Piazza dell'Ospedale Maggiore, 3  
20162 Milan  
Italy +393384774242  
[davide.muratori@ospedaleniguarda.it](mailto:davide.muratori@ospedaleniguarda.it)

