

## Case Report

# Double Transmigration and Hyperdontia

Simon Camilleri

### ABSTRACT

Transmigrated teeth are rare, though reports have increased with the advent of panoramic radiography. Ectopic eruption of canines and other dental anomalies as retained deciduous teeth and supernumerary teeth have a genetic etiology and may be linked. A case report is presented which exhibits transmigration of both a mandibular canine and lateral incisor as well as the presence of a supplemental premolar and retained deciduous molar roots. The possible etiology of these abnormalities is discussed.

**KEY WORDS:** Canine; Lateral incisor; Transmigration; Odontome; Mandible

### INTRODUCTION

Transmigration of the mandibular canine is an unusual event.<sup>1</sup> Diagnosis is usually by radiography, the incidence having increased over the past 30 years with the introduction of dental panoramic tomography (DPT).<sup>2</sup> The etiology is unknown, though several mechanisms have been proposed. Tumors, cysts, and odontomes may cause malposition of teeth if they lie in the path of eruption of teeth. Other possible etiologic factors suggested by some authors are premature loss of deciduous teeth, retention of the deciduous canine, crowding, spacing, supernumerary teeth, excessive length of the crown of the mandibular canines, cystic lesions, and an abnormally strong eruption force.<sup>3-8</sup> A genetic etiology has also been proposed.<sup>9</sup>

Observation, exposure<sup>10</sup> and orthodontic alignment,<sup>11</sup> transplantation,<sup>12</sup> and extraction<sup>13</sup> are all possible treatment options, though extraction is the most popular.

Multiple transmigrations are even rarer.<sup>14</sup> Here is presented a patient with transmigration of a mandibular canine and the adjacent lateral incisor, together with the presence of a supplemental tooth of the premolar series.

### CASE REPORT

The patient, a fit 13-year-old girl, was referred to the Primary Dental Care Department at St Luke's Hospital

for investigation of an unerupted lower left permanent mandibular canine. Her dental history was one of irregular attendance with no previous extractions. Her mother did not notice anything unusual about the development of her dentition.

Intraoral examination found a Class I incisor relation with mild crowding in the lower left premolar/canine area and a well-aligned upper arch. Carious lesions were evident on the molar teeth.

The lower left deciduous canine was retained and firm and the succedaneous canine was not palpable. There was also a supplemental tooth resembling a lower premolar. The crown was somewhat abnormal in shape, being wider and flatter with shallower cusps and wider fissures. A lower incisor was missing from the arch.

DPT (Figure 1) showed two unerupted, transmigrated teeth lying close to the lower border of the mandibular symphysis. The follicles of both teeth were enlarged. The crown of the distal tooth seemed smaller than that of the mesial tooth. The root of the supplemental premolar was smaller and less well formed than its fellows. Third molars were present. Supplementary intraoral views (Figure 2a,b) showed the crown of the unerupted mesial tooth lying lingual to the line of the arch, while that of the distal tooth was in the line of the arch.

Prescribed treatment was extraction of both unerupted teeth under a general anesthetic. The retained deciduous canine was left in situ pending referral to the School Dental Clinic for conservation and an orthodontic opinion. The surgeon confirmed that the extracted teeth were normal in shape and size, though unfortunately the teeth had been subsequently thrown away.

Healing was uneventful and a follow-up radiograph

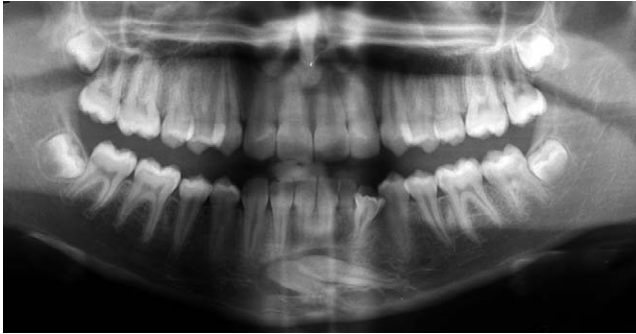---

Senior Lecturer, Department of Dental Surgery, Medical and Dental School, University of Malta.

Corresponding author: Dr Simon Camilleri, Department of Dental Surgery, University of Malta Medical School, Guardamangia, Floriana MSD 06, Malta (e-mail: xmun@onvol.net)

Accepted: September 2006. Submitted: July 2006.

© 2007 by The EH Angle Education and Research Foundation, Inc.



**Figure 1.** Dental panoramic tomography showing transmigrated lower left canine and lateral incisor. A supplemental lower left premolar is also present. Retained deciduous second molar roots are visible distal to the lower second premolars.

one year later showed no further abnormality. The patient accepted to have her carious teeth restored, but declined any sort of orthodontic treatment.

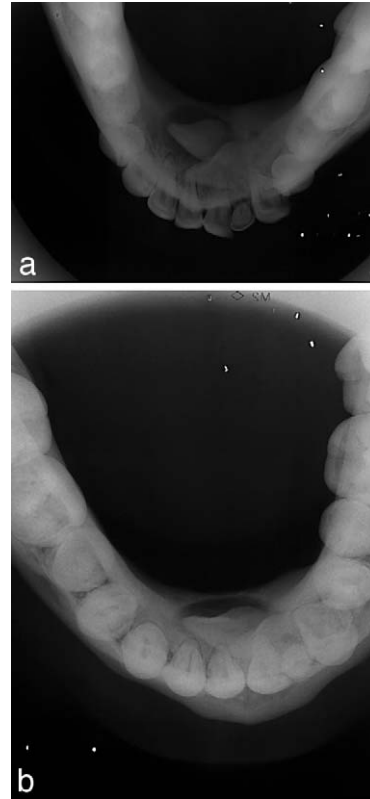
This case shows several unusual features. Transmigrated canines are rare. However, this is the first case where transmigration of a lateral incisor has been recorded. Furthermore, a supplemental premolar had erupted into the arch, adjacent to the retained deciduous canine. It is not unusual for ectopic mandibular canines to be associated with an odontome,<sup>10</sup> however, these are usually of abnormal shape and fail to erupt.

In their review of the literature, Shapira and Kufnec<sup>15</sup> reviewed 73 cases of transmigrated canines. Seven cases (9.5%) exhibited hypodontia while five cases (7%) with odontomes were found. In three of these (4%), both anomalies were present. Taguchi<sup>10</sup> suggests odontomata as a possible cause of aberrant eruption. Ectopic maxillary canines are associated with hypodontia, but ectopic mandibular canines are associated with both hypo- and hyperdontia. One explanation may be that the control of dental lamina proliferation is regulated differently in the maxillary and mandibular arches.<sup>16</sup>

Camilleri and Scerri<sup>17</sup> presented a series of five transmigrated canines, of which four exhibited one or more inheritable dental anomaly. The most common anomaly was ectopic eruption of other teeth, namely the maxillary canines, though one case also had ectopic lower second premolars. The presence of supernumerary teeth together with canine-lateral incisor transmigration of these teeth is consistent with the theory that several developmental disorders have a common, hereditary etiology,<sup>18,19</sup> although no other family member exhibited any similar dental anomaly.

A further unusual feature is that the crown of the mesial tooth is on the lingual side of the arch. Transmigrated teeth are usually quoted as being buccal.<sup>12</sup>

The intraosseous stage of tooth eruption involves



**Figures 2a,b.** Standard and true occlusal views of the mandible showing the position of the crowns.

bone resorption to form an eruption pathway and bone formation, to move the tooth into the eruption pathway. These events are regulated by the dental follicle which determines the direction and timing of tooth eruption. Loss of synchronization of osteoblast-osteoclast signaling may lead to complications.<sup>20</sup> The overall delay of eruption and ankylosis of teeth associated with cases of ectopic eruption may point to a localized defect in osteoclast or osteoblast function.

It is not surprising that eruption anomalies may affect more than one type of tooth.<sup>18</sup> Because the eruption process is common to all teeth, it is unlikely that the mechanisms of eruption of different teeth are due to the action of different genes. Therefore, a defect in the eruption process may reasonably be expected to affect all teeth to some degree. Variations in temporal and spatial gene expression of the mutant genes as well as regional differences in regulation may account for the range of eruption anomalies seen.

## REFERENCES

1. Aydin U, Yilmaz HH, Yildirim D. Incidence of canine impaction and transmigration in a patient population. *Dentomaxillofac Radiol.* 2004;33:164–169.
2. Costello JP, Worth JC, Jones AG. Transmigration of permanent mandibular canines. *Br Dent J.* 1996;181:212–213.
3. Ando S, Aizawa K, Nakashima T, Sanka Y, Shimbo K, Ki-

- yokawa K. Transmigration process of the impacted mandibular cuspid. *J Nihon Univ Sch Dent*. 1964;6:66–71.
4. Shapira Y, Mischler WA, Kuftinec MM. The displaced mandibular canine. *ASDC J Dent Child*. 1982;49:362–364.
  5. Miranti R, Levbarg M. Extraction of a horizontally transmigrated impacted mandibular canine: report of case. *J Am Dent Assoc*. 1974;88:607–610.
  6. Javid B. Transmigration of impacted mandibular cuspids. *Int J Oral Surg*. 1985;14:547–549.
  7. Joshi MR, Shetye SB. Transmigration of mandibular canines: a review of the literature and report of two cases. *Quintessence Int*. 1994;25:291–294.
  8. Al-Waheidi EM. Transmigration of unerupted mandibular canines: a literature review and a report of five cases. *Quintessence Int*. 1996;27:27–31.
  9. Peck S. On the phenomenon of intraosseous migration of nonerupting teeth. *Am J Orthod Dentofacial Orthop*. 1998;113:515–517.
  10. Taguchi Y, Kuroi J, Kobayashi H, Noda T. Eruption disturbances of mandibular permanent canines in Japanese children. *Int J Paediatr Dent*. 2001;11:98–102.
  11. Abbott DM, Svirsky JA, Yarborough BH. Transposition of the permanent mandibular canine. *Oral Surg Oral Med Oral Pathol*. 1980;49:97.
  12. Howard RD. The anomalous mandibular canine. *Br J Orthod*. 1976;3:117–121.
  13. Thoma KH. *Oral Surgery*. Vol 2. St Louis, Mo: CV Mosby; 1952.
  14. Joshi MR. Transmigrant mandibular canines: a record of 28 cases and a retrospective review of the literature. *Angle Orthod*. 2001;71:12–22.
  15. Shapira Y, Kuftinec MM. Intraosseous transmigration of mandibular canines—review of the literature and treatment options. *Compend Contin Educ Dent*. 1995;16:1014,1018–1024.
  16. Wang XP, Aberg T, James MJ, Levanon D, Groner Y, Thesleff I. Runx2 (Cbfa1) inhibits Shh signaling in the lower but not upper molars of mouse embryos and prevents the budding of putative successional teeth. *J Dent Res*. 2005;84:138–143.
  17. Camilleri S, Scerri E. Transmigration of mandibular canines—a review of the literature and a report of five cases. *Angle Orthod*. 2003;73:753–762.
  18. Bjerklin K, Kuroi J, Valentin J. Ectopic eruption of maxillary first permanent molars and association with other tooth and developmental disturbances. *Eur J Orthod*. 1992;14:369–375.
  19. Peck S, Peck L, Kataja M. The palatally displaced canine as a dental anomaly of genetic origin. *Angle Orthod*. 1994;64:249–256.
  20. Marks SCJ, Schroeder HE. Tooth eruption: theories and facts. *Anat Rec*. 1996;245:374–393.