

# **Case Number 1**

## **Familial Adenomatous Polyposis**

*John Xuereb and Yana Marie Dimech*

*Reviewed by: Mr. Dennis T. Gatt L.R.C.P.(Lond.), F.R.C.S.(Eng.), F.R.C.S.(Edin.)*

### **Case summary:**

#### **Demographic details:**

Ms. OC, female, 17 years.

Referred from: home due to strong family history.

OC, a 17-year-old female, was referred due to a strong family history of Familial Adenomatous Polyposis. Multiple relatives (mother, two uncles, several cousins and others) have had Familial Adenomatous Polyposis and had undergone proctocolectomy to prevent the benign polyps from undergoing malignant transformation. The patient presented with no signs and symptoms. On colonoscopy, multiple polyps were found at 10 cm, 15 cm, 40 cm, 80 cm, 110 cm and even in the caecum. The patient subsequently underwent elective Restorative Proctocolectomy with an Ileal Pouch Reservoir. No defunctioning ileostomy was created but the patient was instead managed on TPN (Total Parenteral Nutrition) post-operatively for 2 weeks until a gastrografen small bowel study confirmed the integrity of the pouch and the anastomosis. The patient will be followed up by means of yearly pouchoscopy to exclude the possibility of malignant change at the Transitional Zone between the anal canal and the pouch.

### **Presenting complaint:**

The patient was admitted for elective restorative proctocolectomy with an ileal pouch, after being diagnosed with Familial Adenomatous Polyposis on colonoscopy.

### **History of presenting complaint:**

The patient has a strong family history of Familial Adenomatous Polyposis. She presented with no signs and symptoms. She complains of no bleeding per rectum, no nausea, no abdominal pain, no pyrexia and no change in bowel habits. Despite the presence of so many polyps in her colon she passed stools regularly with no changes in frequency, colour and consistency.

### **Past medical and surgical history:**

#### **Past medical history:**

- Sinusitis
- Allergic Rhinitis

#### **Past surgical history:**

- Tonsillectomy and Adenoidectomy (16/02/2001)

### **Drug history:**

Nil to note. No known drug allergies.

### **Family history:**

OC has a strong family history of Familial Adenomatous Polyposis. Multiple relatives; including her mother, two uncles, several cousins and other distant relatives have had Familial Adenomatous Polyposis and were operated upon, on confirmation of the diagnosis.

### **Social history:**

Patient still lives with her parents. She has stopped attending school after her O-levels and is currently working at Methode Electronics Malta Ltd.

The patient is a social drinker and does not smoke or make use of recreational drugs.

### **Systemic inquiry:**

- General Health: Good and active. Patient looked comfortable after operation
- Cardiovascular System: Nil to note
- Respiratory System: Allergic Rhinitis and Sinusitis
- Gastrointestinal Tract: Nil to note
- Genitourinary System: Nil to note
- Central Nervous System: Headaches associated with sinusitis
- Musculoskeletal System: Nil to note
- Endocrine System: Nil to note

### **Discussion of results of general and specific examination:**

General examination of the patient was unremarkable. The patient appeared healthy, with no physical signs and symptoms of Familial Adenomatous Polyposis. The patient was not pale, jaundiced or cyanosed. There were no evident signs of recent weight loss and the patient denied recent rapid weight loss. She was afebrile.

Cardiovascular, respiratory and abdominal examinations were also unremarkable. These revealed normal heart sounds S1+S2+0, with equal air entry in both lungs and normal vesicular breath sounds. On the abdomen no swelling or scars were observed. The abdominal examination did not reveal any masses or organomegaly. There was no guarding or rebound tenderness. Normal bowel sounds were auscultated and stools were normal.

### **Differential diagnosis:**

- MUTYH associated polyposis (MAP)
- Juvenile polyposis
- Peutz-Jeghers Syndrome
- Mixed Adenomatous hyperplastic Polyposis
- Hyperplastic Polyposis syndrome
- Colonic lymphoid hyperplasia

## **Diagnostic procedures:**

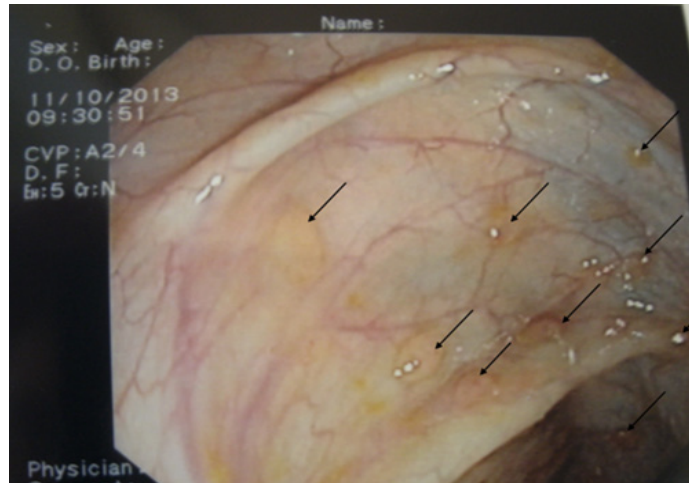
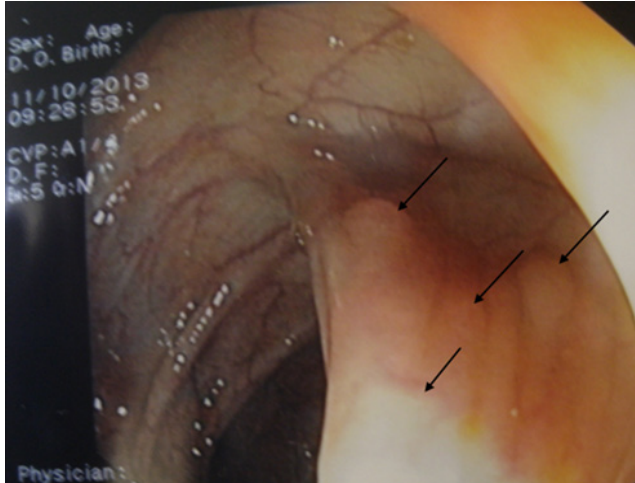
### **Instrumental exams:**

**Test:** Colonoscopy .

**Justification for test:** Strong family history of Familial Adenomatous Polyposis.

**Results:** Multiple polyps at 10 cm, 15 cm, 40 cm, 80 cm, 110 cm and the caecum. More than 30 polyps were present at 80 cm.

**Conclusion:** Morphology suggestive of Familial Adenomatous Polyposis.



*Figures 1 and 2: Colonoscopy showing multiple polyps.*

### **Laboratory exams:**

**Test:** Biopsy for histology from colonoscopy.

**Justification for test:** Multiple polyps on colonoscopy.

**Results:** Biopsies from colon at 100 cm show portion of normal colonic mucosa with a single small area of crypt epithelial hyperplasia resembling edge of hyperplastic polyp.

Biopsies from colon at 90 cm, 40 cm, 15 cm and 10 cm all show portions of colonic mucosa with areas of mild crypt epithelial dysplasia, resembling low grade tubular adenoma. There is no evidence of severe dysplasia or other abnormal feature of note.

**Conclusion:** The colon at 100 cm shows hyperplastic polyp while the colon at 90 cm, 40 cm, 15 cm and 10 cm shows low grade tubular adenoma.

**Test:** Proctocolectomy bowel specimen sections for histology.

**Justification of test:** To confirm diagnosis and exclude high grade dysplasia or invasive adenocarcinoma after restorative proctocolectomy with ileal pouch-anal anastomosis.

**Results:** Sections from proctocolectomy specimen showed multiple small tubular adenomas with low grade dysplasia. Numerous prominent lymphoid follicles were also present. There was no evidence of high grade dysplasia or invasive adenocarcinoma. Sections from small bowel were unremarkable. Both surgical margins were unremarkable. All of the twenty retrieved lymph nodes show sinus histiocytosis and reactive follicular hyperplasia.

**Conclusion:** Multiple tubular adenomas with low grade dysplasia, typical of Familial Adenomatous Polyposis and reactive lymph nodes, typical of inflammatory and immune reactions, were diagnosed.

## **Therapy:**

### **Surgical therapy:**

**Pre-operative:** The patient was admitted to the surgical wards from admission lounge a day before the surgery. The patient was started on Klean prep, for bowel cleansing. Four sachets were taken in total, one sachet with one litre of water every two hours. The patient was allowed fluids for that day but then nil by mouth from midnight. TED stockings were applied. An ECG and cross-match were carried out. Stool charting was started. Informed consent was obtained.

**Operation:** Restorative proctocolectomy with ileal pouch-anal anastomosis.

Total mobilisation of the colon including; the caecum, ascending colon, transverse colon, splenic flexure, descending colon, sigmoid colon and the rectum was performed. The dissection at the pelvic brim was carried out, very close to the colon to preserve the Nervi Erigentes. The rectum was dissected by a combination of blunt and sharp dissection, all the way down to the pelvic floor and transected with a Contour Stapler. The terminal ileum was also divided at this stage, with a GIA stapler. A 35 cm Ileal Pouch Reservoir was created from the terminal ileum in a J shape using 3 firings of the GIA stapler. The lower end of the J was then anastomosed to the anal canal using a CEA 28 stapler and the doughnuts were inspected to make sure they were not broken. The abdomen was closed with drainage to the pelvis and no defunctioning ileostomy was used.

A central venous catheter was also inserted during the operation for Total Parenteral Nutrition (TPN). The right jugular vein was used.

**Post-operative:** A naso-gastric tube was inserted. Total Parenteral Nutrition was started three days after surgery; when serum potassium, calcium, magnesium and phosphates were all in normal ranges. The abdominal drainage was minimal on the fourth day following surgery. The patient was also passing flatus and greenish liquid stools on the fourth day following surgery.

The post-operative medications were as follows:

<b>Drug Name (Generic)</b>	<b>Dosage</b>	<b>Route</b>	<b>Frequency</b>	<b>Reason</b>
Paracetamol	1 g	IV/PO/PR	4-6 hrly / PRN	Pain relief
Ciprofloxacin	200 mg	IV	BD	Broad spectrum antibiotic (prophylaxis)
Metronidazole (Flagyl)	500 mg	IV	TDS	Prophylaxis against anaerobic organisms and protozoa
Diclofenac (Voltaren)	500 mg	PO	PRN	Pain relief
Magnesium sulphate 50%	2 mls in 100 mls normal saline	IV	BD	Acts as a supplementary analgesic therapy to suppress the acute post-operative pain
Clexane	4000 units	SC	QD	Prophylaxis for deep vein thrombosis and pulmonary embolism
Prochlorperazine (Stemetil)	12.5 mg	IM	PRN	To control nausea and vomiting post-operatively
Pethidine	50 mg	IM	PRN	Pain relief

## **Diagnosis:**

Familial Adenomatous Polyposis was diagnosed by means of colonoscopy and histological examination of the biopsies taken from the various polyps found. The colonoscopy was indicated because of the strong family history. The diagnosis was then confirmed after restorative proctocolectomy by more detailed histological evaluation of the entire colonic specimen. In this case, high grade dysplasia and invasive adenocarcinoma were also excluded.

Familial Adenomatous Polyposis (FAP) is classically characterised by the development of numerous polyps (polyposis) in the colon and rectum at atypical early ages, usually during the second decade of life<sup>1-2</sup>. This condition carries a 100% lifetime risk of malignant transformation of adenomas into colorectal carcinoma<sup>3</sup>. FAP is inherited as an autosomal dominant disease caused by the germ-line mutation of the APC (Adenomatous Polyposis Coli) gene<sup>4</sup>.

FAP is typically asymptomatic, especially in children and adolescents, until the polyps are large and numerous sufficiently to start causing rectal bleeding, constipation, diarrhoea, change in bowel habits or abdominal pains. Some patients also evolve palpable abdominal masses and weight loss. Many patients remain asymptomatic until they develop colorectal carcinoma (CRC)<sup>2</sup>.

On colonoscopy, classic FAP presents with hundreds and thousands of colorectal adenomatous polyps. These typically start to develop in early childhood, predominately at the rectosigmoid and later on, in adolescence, these are typically established throughout the colon<sup>2</sup>. It is shown that at 15 years of age 50% of the patients have established adenomas while at 35 years of age up to 95% have developed adenomas<sup>5</sup>. Though colorectal carcinoma in the majority of cases develops by the age 40-50 years it can still develop in children<sup>2</sup>.

FAP patients also commonly present with extra-colonic gastrointestinal features. These include fundic gland polyps in the stomach, adenomatous polyps in the duodenum and periampullary region and small bowel adenoma<sup>2</sup>. Fundic gland polyps have the potential to progress to carcinoma but rarely do so<sup>6</sup>. About 5% of adenomatous polyps in the duodenum and periampullary region progress to malignancy in a 10-year period<sup>7</sup>. Small bowel polyps also carry a risk for malignant transformation though this is lower than the risk in duodenal and ampullary neoplasm<sup>2</sup>.

FAP may also present with any of its extraintestinal manifestations. These include congenital hypertrophy of the retinal pigment epithelium, dental abnormalities (including supernumerary teeth, congenital absence of one or more teeth and unerupted teeth), osteomas, desmoid tumours and extracolonic cancers (including thyroid, liver, bile ducts and central nervous system tumours). Gardner's syndrome is a clinical variant of FAP where the extra-colonic features are prominent<sup>2</sup>.

A milder form of FAP can present, Attenuated FAP, is a less aggressive variant where one develops fewer adenomas and the adenomas and colorectal carcinoma both develop at a later age<sup>2</sup>.

Nearly every patient with FAP will develop colorectal carcinoma if they are undiagnosed or untreated. However, at present it is very atypical to find patients presenting with symptoms of the colorectal carcinoma since most of the patients today are diagnosed and treated surgically before there is malignant transformation<sup>2</sup>.

A high clinical index of suspicion is needed as patients are usually asymptomatic but may present with a strong family history. Questions such as; whether anyone in the family ever had cancer, what type of cancer and at what age it presented are vital in this case. One may also identify extra-colonic manifestations of FAP, on which grounds a physician should perform a flexible sigmoidoscopy or a colonoscopy. Genetic testing is also of use in FAP. Its main role is in screening and in the early asymptomatic stages of the

disease in patients with a strong family history. Numerous types of genetic tests are currently available to investigate for APC germline mutations. Direct sequencing of the APC gene is the preferred and most commonly used method at present<sup>2</sup>.

The aim of management in FAP patients is tumour prevention while maintaining a good quality of life. This is usually obtained, after their genetic diagnosis and endoscopic procedures, by prophylactic colorectal surgery. Since colorectal carcinoma is rare in asymptomatic children and adolescents, these should be followed up and then at around 16 -18 years of age an elective procedure is planned<sup>8</sup>. Multiple surgical options are available. These include; subtotal colectomy with ileorectal anastomosis (IRA), total proctocolectomy with ileostomy and proctocolectomy with or without mucosectomy and ileal pouch anal anastomosis (IPAA). The latter procedure is preferred for classical FAP, especially if numerous rectal adenomas are present<sup>9,10</sup>.

Post-operatively it is crucial to follow-up these patients. Initially, one should deal with the physical and psychological adjustments to surgery and identifying desmoid tumour formation which is associated with FAP<sup>2</sup>. In IRA, due to the risk of rectal adenomas and carcinomas, life-long rectal endoscopic investigations should be carried out annually. Also, studies have shown that after restorative proctocolectomy, adenomas and even adenocarcinomas can evolve in the ileo-anal pouch and the transitional anal zone. Therefore it is vital to undertake endoscopic surveillance of both the pouch<sup>11</sup> and the transitional anal zone<sup>12</sup>.

### **Final treatment and follow ups:**

The patient was kept nil by mouth until a small bowel gastrografen enema was carried out and this confirmed that the pouch and the anastomosis were intact. At this stage she was started on a light diet and the total parenteral nutrition was stopped 17 days post-operatively.

The patient will be followed up by means of yearly pouchoscopy, to exclude the possibility of malignant change at the Transitional Zone between the anal canal and the pouch.



## **Fact Box 1**

### Title: Familial Adenomatous Polyposis

Familial Adenomatous Polyposis (FAP) is an inherited autosomal dominant disease<sup>4</sup>. It classically characterised by the development of numerous polyps (polyposis) in the colon and rectum at atypical early ages, usually during the second decade of life<sup>1-2</sup>. FAP is caused by the germ-line mutation of the APC (Adenomatous Polyposis Coli) gene<sup>4</sup>. This condition carries a 100% lifetime risk of malignant transformation of adenomas into colorectal carcinoma<sup>3</sup>.

Signs and symptoms: FAP is typically asymptomatic until patients develop colorectal carcinoma (CRC). In some cases, especially after adolescence, when polyps are large and numerous sufficiently, symptoms and signs can be elicited. These include:

- Rectal bleeding
- Constipation
- Diarrhoea
- Change in bowel habits
- Abdominal pains
- Palpable abdominal masses
- Weight loss

Risk factors: Family history

Investigations to confirm diagnosis:<sup>2</sup>

- Flexible sigmoidoscopy or colonoscopy
- Biopsy for histology
- Genetic testing

Prevention of Colorectal carcinoma:<sup>9,10</sup>

- Subtotal colectomy with ileorectal anastomosis (IRA)
- Total proctocolectomy with ileostomy
- Proctocolectomy with or without mucosectomy and ileal pouch anal anastomosis (IPAA)

The latter procedure is preferred for classical FAP, especially if numerous rectal adenomas are present.

### **References:**

1. Plawski A, Banasiewicz T, Borun P, et al, Familial adenomatous polyposis of the colon, *Hered Cancer Clin Pract*, 2013; 11(1): 15.
2. Half E, Bercovich D, Rozen P, Familial adenomatous polyposis, *Orphanet J Rare Dis*, 2009; 4: 22.
3. Bussey HJ, Veale AM, Morson BC, Genetics of gastrointestinal Polyposis, *Gastroenterology*, 1978; 74:1325–1330.
4. Groden J, Thliveris A, Samowitz W, et al, Identification and characterization of the familial adenomatous polyposis coli gene, *Cell*, 1991; 66:589–600.
5. Petersen GM, Slack J, Nakamura Y, Screening guidelines and premorbid diagnosis of familial adenomatous polyposis using linkage, *Gastroenterology*, 1991; 100:1658–1664.
6. Bianchi KL, Buerke CA, Bennett AE, et al, Fundic gland polyp dysplasia is common in familial adenomatous Polyposis, *Clin Gastroenterol Hepatol*, 2008; 6:180–185.
7. Groves CJ, Saunders BP, Spigelman AD, et al, Duodenal cancer in patients with familial adenomatous polyposis (FAP): results of a 10 year prospective study, *Gut*, 2002; 50:636–641.
8. Vasen HF, Möslein G, Alonso A, et al, Guidelines for the clinical management of familial adenomatous polyposis (FAP),

Gut, 2008; 57:704–713.

9. Aziz O, Athanasiou T, Fazio VW, et al, Meta-analysis of observational studies of ileorectal versus ileal pouch-anal anastomosis for familial adenomatous Polyposis, Br J Surg, 2006; 93:407–417.
10. Ziv Y, Church JM, Oakley JR, et al, Results after restorative proctocolectomy and ileal pouch anal anastomosis in patients with familial adenomatous polyposis and coexisting colorectal cancer, Br J Surg, 1996; 83:1578–1580.
11. Hurlstone DP, Saunders BP, Church JM, Endoscopic surveillance of the ileoanal pouch following restorative proctocolectomy for familial adenomatous Polyposis, Endoscopy, 2008; 40:437–42.
12. Ooi BS, Remzi FH, Gramlich T, et al, Anal transitional zone cancer after restorative proctocolectomy and ileoanal anastomosis in familial adenomatous polyposis: report of two cases, Dis Colon Rectum, 2003; 46:1418–1423.