

The elephant man syndrome

Richard Pullicino,¹ Reuben Grech²

¹Medical Imaging Department, Mater Dei Hospital, Msida, Malta

²Department of Neuroradiology, Beaumont Hospital, Dublin, Ireland

Correspondence to

Dr Richard Pullicino, richard.pullicino@gmail.com

DESCRIPTION

We describe a case of Proteus syndrome in a 34-year-old man who started to notice growths over his left frontal and temporal regions about 15 years ago. An abdominal ultrasound confirmed splenomegaly which was palpable on clinical examination. A skull X-ray showed well-circumscribed lesions over the left frontal bone and at the mastoid processes with a hazy appearance of the matrix, a narrow zone of transition and no periosteal reaction. CT demonstrated hyperostosis of the skull (figure 1).

Proteus syndrome is an exceedingly rare hamartomatous congenital disorder characterised by overgrowth of tissues originating from any of the three germinal layers, thus potentially affecting any system within the body, and the causative mutation has been mapped to the AKT1 gene.¹ Presentation is highly variable; however, skeletal deformity is virtually always present,² with hyperproliferation and hyperostosis of the osteoid component of the bone. In this case, the bone features together with lobulated splenomegaly had a mosaic distribution, appeared sporadically and continued to increase in size with time. This was consistent with a diagnosis of Proteus syndrome.³

Affected individuals have a high incidence of neoplasia including testicular and ovarian tumours, meningiomas and monomorphic adenomas of the parotid gland. Pulmonary embolism and deep vein

thrombosis secondary to underlying vascular malformations may result in premature death.

Learning points

- ▶ Proteus syndrome should be considered in the differential diagnosis of asymmetrical soft tissue hypertrophy and hyperostosis.
- ▶ Since it is an example of genetic mosaicism, patients with Proteus syndrome can present with a variety of signs and symptoms.

Contributors RP and RG contributed in the gathering of information related to the case, the generation of reconstructions and in writing the final draft of the manuscript.

Competing interests None.

Patient consent Obtained.

Provenance and peer review Not commissioned; externally peer reviewed.

REFERENCES

- 1 Lindhurst MJ, Sapp JC, Teer JK, *et al*. A mosaic activating mutation in AKT1 associated with the Proteus syndrome. *N Engl J Med* 2011;365:611–19.
- 2 Jamis-Dow CA, Turner J, Biesecker LG, *et al*. Radiologic manifestations of proteus syndrome. *Radiographics* 2004;24:1051–68.
- 3 Biesecker L. The challenges of Proteus syndrome: diagnosis and management. *Eur J Hum Genet* 2006;14:1151–7.

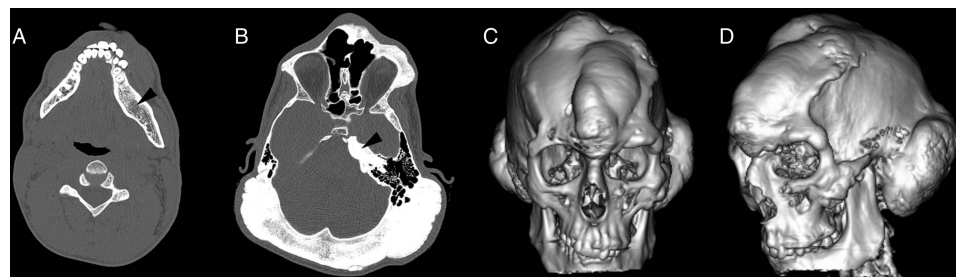


Figure 1 Axial CT images demonstrating osseous expansion with medullary ground glass change in the body of the left mandible (arrow—A). Radiological differential diagnosis includes polyostotic fibrous dysplasia. Hyperostosis is seen to affect the entire occipital bone, the left petrous apex (arrow—B) and the left infraorbital margin. Reconstructed images (C and D) revealing asymmetrical osseous overgrowth resulting in characteristic craniofacial abnormalities.



To cite: Pullicino R, Grech R. *BMJ Case Rep* Published online: [please include Day Month Year] doi:10.1136/bcr-2013-201541

Copyright 2014 BMJ Publishing Group. All rights reserved. For permission to reuse any of this content visit <http://group.bmj.com/group/rights-licensing/permissions>.
BMJ Case Report Fellows may re-use this article for personal use and teaching without any further permission.

Become a Fellow of BMJ Case Reports today and you can:

- ▶ Submit as many cases as you like
- ▶ Enjoy fast sympathetic peer review and rapid publication of accepted articles
- ▶ Access all the published articles
- ▶ Re-use any of the published material for personal use and teaching without further permission

For information on Institutional Fellowships contact consortiasales@bmjgroup.com

Visit casereports.bmj.com for more articles like this and to become a Fellow