


# Lasers and ancillary treatments for scar management Part 2: Keloid, hypertrophic, pigmented and acne scars

Scars, Burns & Healing  
Volume 3: 1–16  
DOI: 10.1177/2059513116689805  
Reprints and permissions:  
sagepub.co.uk/journalsPermissions.nav  
© The Author(s) 2017  
journals.sagepub.com/home/sbh  


Rory Boyd McGoldrick<sup>1</sup>, Evgenia Theodorakopoulou<sup>1</sup>, Ernest Anthony Azzopardi<sup>2</sup> and Maxwell Murison<sup>1</sup>

## Abstract



The formation of a wide range of excessive scars following various skin injuries is a natural consequence of healing. Scars resulting from surgery or trauma affect approximately 100 million people per annum in the developed world and can have profound physical, aesthetic, psychological and social consequences. Thus, scar treatment is a priority for patient and physician alike. Laser treatment plays an important role in scar management with additional support from ancillary modalities. Subsequent to part 1: Burns scars, part 2 focuses on our strategies and literature review of treatment of keloid, hypertrophic, pigmented and acne scars where lasers are used in conjunction with other measures, and illustrated with case studies.

## Keywords

Corticosteroids, fluorouracil, laser, multimodality scar management, scar, silicone, surgery

## Lay Summary



Scars can result as part of the normal healing process after a burn or other trauma such as surgery or injury. However, there is a range of scarring from 'good' to 'bad' depending on various features of the scars. Some can be lumpy and raised (hypertrophic and keloid scars), have changes in pigmentation (increased or decreased colouration) or have specific features related to the cause (for instance acne scars, burns scars). We review the senior author's experience over twenty years in treating scars with a range of treatments in conjunction with lasers. This is the second and final article in the series looking at 4 main aspects of scarring. In part 1, the focus was burns scars.



In Part 2, we now focus on hypertrophic and keloid scars (thickened raised scars); pigmented scars and acne scars. Lasers play an important role in managing a variety of scars in our practice, which work best in combination with other treatments as described.

## Introduction

Scars are a major disease burden on morbidity, mortality and quality of life.<sup>1,2</sup> In this second manuscript, we review our centre's multimodality approach for scar management, focusing on scar hypertrophy, keloid, acne pigmentation and vascular scarring, based upon experience and backed by evidence.

<sup>1</sup>Welsh Regional Burns, Plastic, Reconstructive Surgery and Laser Unit, Morriston Hospital, Swansea, Wales, UK

<sup>2</sup>Swansea University Medical School, Swansea University, Swansea, UK

### Corresponding author:

Ernest Anthony Azzopardi, Swansea University Medical School, Singleton Campus, Swansea University, Office 203, Floor 2, Institute of Life Sciences 1, Swansea, SA2 8 PP, UK.  
Email: Ernest\_Azzopardi@yahoo.co.uk



## Hypertrophic scars and keloids

Hypertrophic scars are typically confined within the borders of the initial insult and present as immature, linear or widespread. Immature hypertrophic scars are red, on occasion pruritic or painful, mildly raised and are in the process of remodelling. Usually, these scars mature to flat scars. Linear scars are most commonly a result of a healed laceration, or surgical incision. They tend to improve and flatten only slowly with time and hence patients seek help to reduce the symptoms of itchiness and poor appearance. All types may regress to varying degrees spontaneously with time.<sup>3,4</sup> Hypertrophic scar pathogenesis may be related to atypical extracellular matrix metabolism secondary to abnormal and exaggerated fibroblastic activation.<sup>5,6</sup> This manifests histologically as well organised type III collagen but with an overexpression of both types I and III, profibrotic pyridinoline type collagenous crosslinkages, fibronectin deposition with overexpression of interleukins (IL)-4-6, -13 and -21 and underexpression of IL-12 and interferon (IFN)- $\gamma$ .<sup>5,6</sup>

Keloids are defined as excessive scars that invade beyond the borders of the initial insult and do not regress spontaneously. They recur in 45–100% of cases following excision.<sup>3,4</sup> This is due to the fact that the new closure is exposed to the same mechanical, immunological and biochemical forces as the original scar.<sup>3-6</sup> Areas particularly prone include the earlobes, chest, shoulders, upper back and posterior neck. Minor keloids are focally raised, pruritic scars that can occur up to one year following the initial injury. Major keloids are large, raised (>5 mm), dark red scars associated with pain and pruritis and continue to increase in size over years.

Although similar approaches to both hypertrophic and keloid scarring exist in the literature, there is no universally accepted regimen. Most commonly used techniques lack well-designed randomised controlled studies.

### *Prophylaxis of hypertrophic and keloid scars*

Meticulous wound debridement, removal of foreign and necrotic material, tension-free closure with the least reactive suture material and every attention to avoid infection are effective preventive measures.<sup>7,8</sup> After wound closure, methods include tension reduction either mechanically<sup>9,10</sup> or neurotoxically mediated,<sup>11</sup> hydrating occlusive silicone gel dressings<sup>12,13</sup> and pressure garment therapy.<sup>7,14</sup> The earlier this treatment occurs for abnormal immature scars with intact epithelium, the more favourable the outcome. The transition

to a formal treatment regime develops when a true hypertrophic scar or keloid, and not an immature hypertrophic scar, has been diagnosed. Conventional treatment of both hypertrophic scars and keloids commonly involves massage,<sup>15-18</sup> pressure therapy,<sup>19-23</sup> hydrating occlusive silicone dressings,<sup>24-29</sup> corticosteroid injection,<sup>30-32</sup> surgical excision<sup>33-35</sup> and radiotherapy,<sup>36-39</sup> alone or in combination.<sup>30,31</sup> Only hydrating occlusive silicone dressing and corticosteroid injection have been demonstrated effective in randomised controlled trials.<sup>31,40</sup> A comprehensive review of the strength of the evidence in the other first line modalities is available elsewhere<sup>41</sup> and is beyond the scope of this chapter.

### *Prophylaxis of hypertrophic and keloid scars*

**Corticosteroid injection.** Corticosteroid injection, either alone or in combination with other agents, has become one of the most widely practised treatment modalities for hypertrophic scars and keloids.<sup>42,43</sup> These are normally administered intralesionally in the form of insoluble triamcinolone acetonide (0–40 mg mL<sup>-1</sup>). Injections are performed every four to six weeks until pruritic and pain-related symptoms subside and the scar flattens. Response rates vary (50–100% with a recurrence rate of 9–50%<sup>44,45</sup>). Complications are common and 63% experience localised dermal atrophy, ulceration, hypopigmentation or telangiectasia.<sup>46</sup> Significant pain may be controlled by the addition of local anaesthetic. As monotherapy, corticosteroids are most effective for younger keloids, which may completely flatten while older keloids are more resistant.<sup>47</sup> Given these limitations, other agents have been used in combination with corticosteroids to further modulate the hyperproliferative response.

**Fluorouracil.** The senior author advocates the combined use of 5-Fluorouracil (5-FU), a pyrimidine analogue, commonly used as an anti-metabolite chemotherapy reagent. It inhibits thymidylate synthase activity. First used to reduce subconjunctival scarring in the context of glaucoma filtering surgery in 1984,<sup>48,49</sup> it was later used as both a monotherapy and in combination with corticosteroids for the treatment of hypertrophic scars and keloids.<sup>32,50</sup> Combined therapy with concentrations in the range of 40–50 mg mL<sup>-1</sup> has been found to be more efficacious than 5-FU monotherapy,<sup>51-55</sup> with no additional complications.<sup>56</sup> Acting intracellularly, it promotes fibroblastic apoptosis, without necrosis, via inhibition of DNA synthesis in hyperproliferative and metabolically active cells. More recently, Huang et al. demonstrated the possibility of low

dose 5-FU at 1 mg mL<sup>-1</sup> and triamcinolone work together to inhibit fibroblastic proliferation, type I collagen deposition and matrix metalloproteinase-2 induction in vitro, and promote apoptosis.<sup>57,58</sup> Our current approach, however, is to use conventional doses of 50 mg mL<sup>-1</sup> injected intralesionally in combination with 10–40 mg mL<sup>-1</sup> depending on scar resistance and extent every four to six weeks until the scar is flat, soft and symptom-free. The scar is not injected to the point of blanching to avoid ischaemia, ulceration and potential deterioration. Once a plateau is reached, the injections may be given between increasingly longer intervals titrated to response. All patients are informed of the fact that initial injections are uncomfortable due to the dense nature of the scar and subsequent injections becoming less so. In addition, local complications such as post-injection pain, ulceration and burning are outlined as is the theoretical risk of 5-FU-induced neutropenia and fetal complications if pregnant. The treatment is not performed during pregnancy or in those patients with bone marrow suppression.

Excision, combined with postoperative 5-FU and triamcinolone injection, can be effective,<sup>33</sup> but must be considered on a case-by-case basis, for example if a patient presents with mature bulky keloid disease of the earlobe or face, or a functionally disabling immature or early-stage hypertrophic scar. It must be remembered that hypertrophic scars mature during a period of at least 12 months and demonstrate decreased contractures, thickening, softening and repigmentation quite often without treatment.<sup>59</sup> Therefore, excision may not be warranted despite the fact recurrence may be low.<sup>60,61</sup> For mature keloidal excision, a complete excision of all scar tissue is performed<sup>62,63</sup> and closure is delivered with minimal tension and suture material leaving everted wound margins. Indeed, the senior author has performed this with the ablative CO<sub>2</sub> laser. Undermining however, is not recommended and sutures should be placed multiplanar to reduce tension.<sup>33</sup> Residual lesional injection is performed thereafter at the time of surgery and continued at four- to six-week intervals titrated to response.

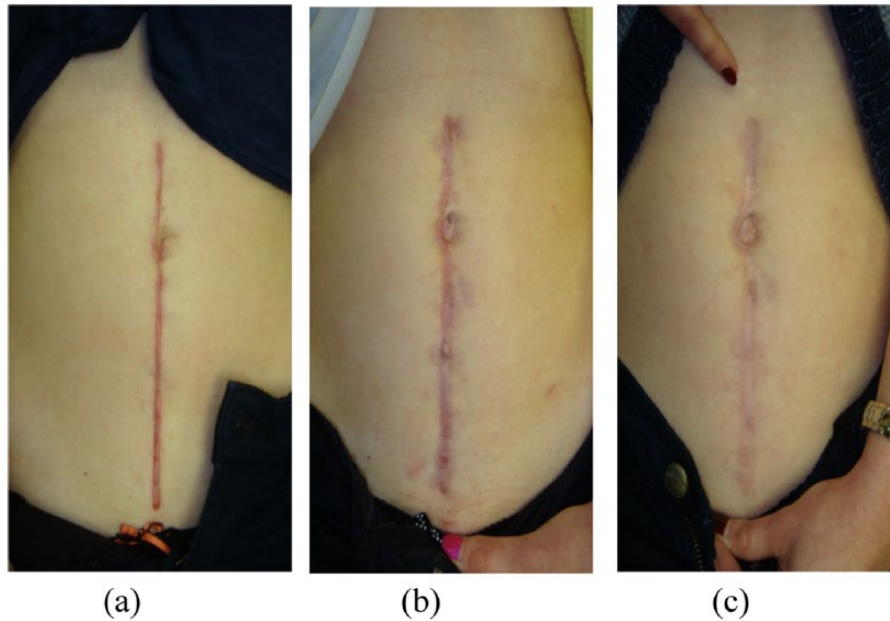
**Intralesional cryosurgery.** This technique evolved from simple cryosurgery, first introduced by Shepard and Dawber.<sup>64</sup> Suitable for small scars only, liquid nitrogen contact or spray technique may induce vascular injury leading to anoxia, scar tissue necrosis, sloughing and thus scar flattening.<sup>65</sup> The process may take two to ten treatment sessions with 20–30 days between each one. Success rates are in the range of 32–74% after two or more treatments, with higher response

rates in hypertrophic scars compared to keloids.<sup>31,66,67</sup> Reported complications include immediate blistering and pain with longer-term risks of dermal atrophy that can either hyper- or hypopigment.<sup>67,68</sup> In contrast, intralesional cryosurgery involves placing a novel intralesional cryoneedle (Cryoshape™) within the long axis of the scar. The probe consists of an elongated double-lumen uninsulated needle with a safety vent and a cutting, sealed, distal tip designed to enhance the penetration of the often dense, hard scar. To the proximal end of the probe is connected liquid nitrogen that is pressurised to circulate through the needle, which leads to an ice ball forming around the cryoneedle leaving the abutting scar tissue completely frozen. There is an apparent reduction in myofibroblasts and mast cells with an accompanying normalisation of collagen structure and organisation.<sup>69</sup> First described by Weshahy in 1993<sup>70</sup> and later popularised by Har-Shai et al.,<sup>69,71–77</sup> the technique has shown increased efficacy over simple cryosurgery,<sup>71–77</sup> with reports of clinical efficiency in the range of 20–75% scar volume reduction.<sup>71,78,79</sup> Complications include pain (although less than contact cryotherapy<sup>72,80</sup>), peritreatment oedema and epidermolysis, and temporary hypopigmentation. Skin surface temperature is less effected in intralesional cryotherapy and thus melanocyte sparing is a feature accounting for a lower incidence of dyschromia.<sup>81</sup>

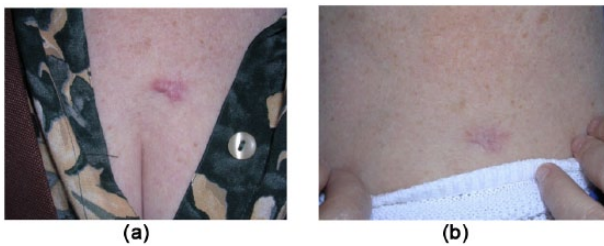**Radiotherapy.** In a small cohort of older adult patients, in whom other treatment options are declined, ionising radiation in combination with intralesional excision, as described, can be used for resistant hypertrophic scars and keloids.<sup>39</sup> Radiation acts to inhibit fibroblast proliferation and collagen synthesis, inducing apoptosis of proliferating cells at doses of 15–30 Gy over six sessions with precise dosimetry with appropriate shielding in the immediate postoperative period.<sup>31,36,37,82</sup> Radiotherapy is restricted to older adults given the small but theoretical risk of carcinogenesis<sup>38,39</sup> but is efficacious. Success rates in the literature are in the range of 25–88%,<sup>83,84</sup> but this is complicated by the retrospective nature of studies with variable follow-up periods and poorly defined clinical assessment. Therefore, evidence remains variable and there is a need for randomised prospective studies with objective clinical evaluation and long-term follow-up.

### Hypertrophic and keloid scar patient case illustrations

1. A 40-year-old woman, Fitzpatrick type II, presented two years following a mid-line



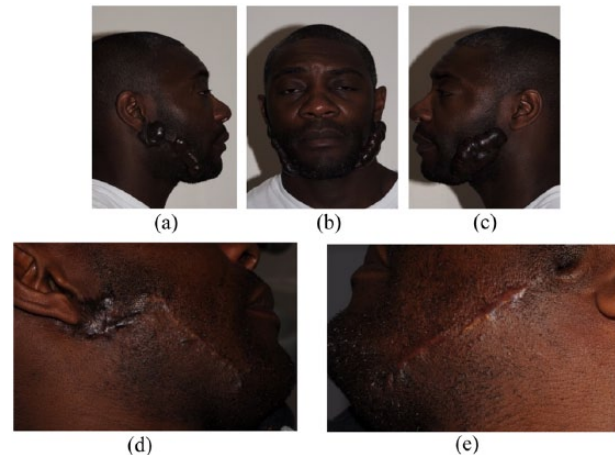
**Figure 1.** Photographs are pretreatment (a), six weeks after first treatment (b) and six weeks after last treatment (c).



**Figure 2.** (a) At presentation; (b) 24.9 months post treatment showing improvement in colour, pruritus and scar thickness.

laparotomy with hypertrophic scarring. She complained of pruritus, pain and discomfort from clothing. The shortened scar limited full extension and splinted the costal margin to the pelvis. She was treated with intralesional chemotherapy and pharmacotherapy. She underwent three cycles of intralesional 100 mg of 5-FU and 40 mg of Triamcinolone six weeks apart. Improvement in colour, pruritus and scar thickness.

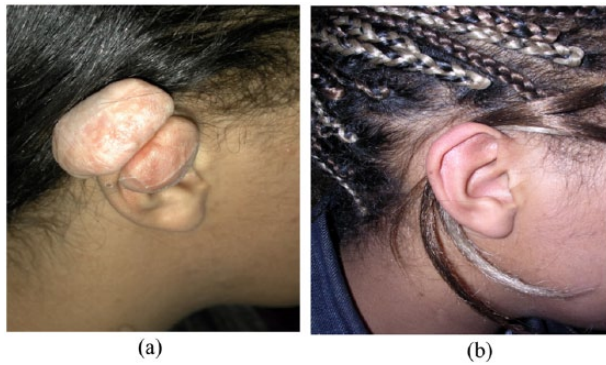
2. A 78-year-old woman, Fitzpatrick type II, presented with a hypertrophic scar following excision of a squamous cell carcinoma from her left presternal region. She complained of itching, pain and the raised appearance. She underwent three cycles of intralesional 50 mg of 5-FU and 10 mg of Triamcinolone six weeks apart.
3. A 38-year-old man, Fitzpatrick type VI, presented with a five-year history of bilateral



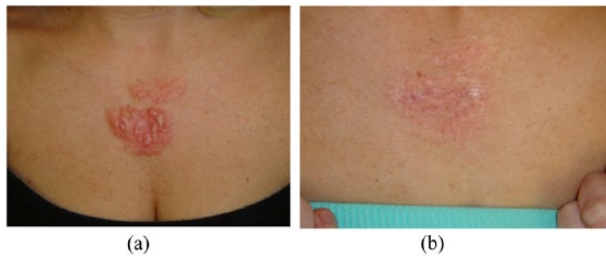
**Figure 3.** (a–c) Pre treatment and (d, e) post treatment.

recalcitrant mandibular margin keloids with intense pruritus from repeated folliculitis related to shaving trauma. Failed previous pharmacotherapy with stand-alone intralesional triamcinolone and also radiotherapy. The patient underwent complete scar excision and 200 mg of 5-FU and 40 mg of Triamcinolone injection at closure which was complicated on the right by delayed wound healing secondary to a small proximal wound dehiscence. Two months postoperatively, once all wounds were healed, residual keloid margin intralesional injection of the same mixture was repeated every six weeks. Nine cycles have passed and the time between injections





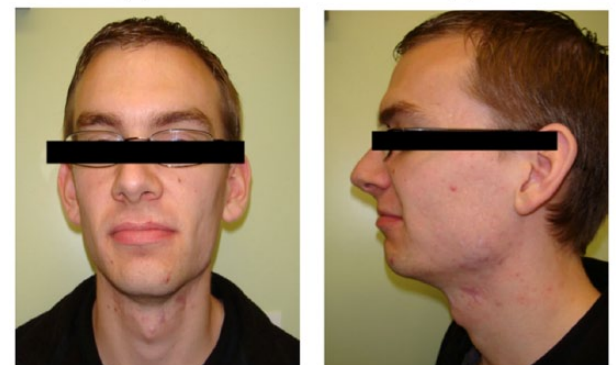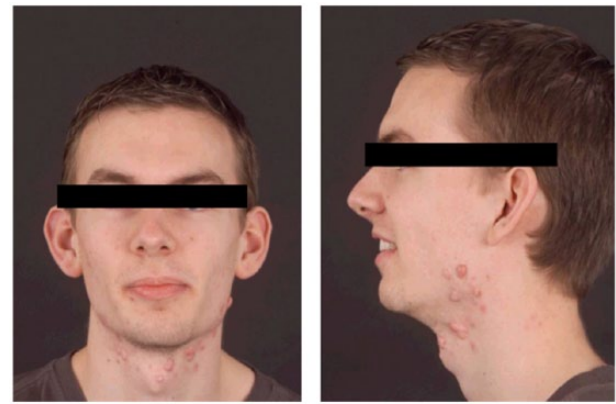
**Figure 4.** (a) Pretreatment and (b) four years post treatment, two years after last scar injection. Management: intralesional excision and 50 mg of 5-FU and 10 mg of Triamcinolone injection at closure.



**Figure 5.** Recalcitrant acne vulgaris-related keloid scarring. (a) Pre treatment and (b) post treatment.

will now be lengthened. The keloid disease load has been controlled with no pruritus and the patient can once again shave. Pre treatment (top row) and post treatment (bottom row).

4. A 22-year-old woman, Fitzpatrick type V, presented with recalcitrant pinna keloid scars from a helical rim piercing with intense pruritus previously treated with a course of stand-alone intralesional triamcinolone. Underwent complete surgical excision of all scar tissue and 50 mg of 5-FU and 10 mg of Triamcinolone injection at closure. Two months postoperatively, once all wounds were healed, margin intralesional injection of the same mixture was repeated every six weeks. The keloid disease load has been controlled with a favourable cosmetic outcome.
5. A 27-year-old woman, Fitzpatrick type II, presented with presternal recalcitrant acne vulgaris-related keloid scars with intense pruritus and tenderness previously treated with topical silicone agents. She underwent intralesional injection of 50 mg of 5-FU and 10 mg of Triamcinolone



**Figure 6.** (a, b) Mature static keloids related to previous acne vulgaris inflammation. (c, d) After nine months there was no recurrence and there was a favourable cosmetic outcome.

injection repeated every six weeks. The keloid disease load has been controlled after 18 injections with a favourable cosmetic outcome and resolution of symptoms. Treatment is ongoing as thickening occurs if treatment interval exceeds six weeks. Pre treatment (left) and post ninth treatment (right).

6. A 24-year-old, Fitzpatrick type II, presented with a five-year history of mature static keloids related to previous acne vulgaris inflammation in the left neck. He complained of the cosmetic appearance of the scars and difficulties shaving. A single ablative CO<sub>2</sub> laser treatment with the Ultrapulse® 2 mm true spot hand piece 175 mJ multiple passes to ablate the keloid to the level of the surrounding epidermis was performed.

### Acne scarring

Acne vulgaris is a common cutaneous disease with a multifactorial pathogenesis that affects a significant proportion of the population. The

**Table 1.** Post acne scars, qualitative global grading system (Goodman and Baron).

Grade	Disease level	Features and tests
I	Macular	These scars are erythematous, hyper- or hypopigmented macules. They do not represent a problem of contour but that of colour.
II	Mild	Mild atrophic or hypertrophic scars that may not be obvious at social distances of 0.5 m or greater and may be covered adequately by makeup or the normal shadow of shaved beard hair in men or normal body hair if extrafacial.
III	Moderate	Moderate atrophic or hypertrophic scarring that is obvious at social distances of 0.5 m or greater and is not covered easily by makeup or the normal shadow of shaved beard hair in men or body hair if extrafacial. Can be flattened by manual stretching of the skin (if atrophic).
VI	Severe	Severe atrophic or hypertrophic scarring that is evident at social distances greater than 0.5 m and is not covered easily by makeup or the normal shadow of shaved beard hair in men or body hair if extrafacial. Cannot be flattened by manual stretching of the skin.

condition may be divided into either comedonal, papulopustular or conglobulate acne or depending on severity, mild moderate or severe. It has a prevalence of over 80% in adolescents and persists in 12–14% of cases into adulthood.<sup>85–91</sup>

Severe acne can lead to significant psychosocial concerns, such as ostracism and withdrawal from society.<sup>92</sup> Pathogenesis is multifactorial and includes the proliferation and colonisation of *Propionibacterium Acne* within the follicles, excessive sebum production with abnormal sebum lipid profiles, androgen dysfunction and follicular hyperkeratinisation.<sup>93</sup> As a consequence, there is associated infrafundibular inflammation, follicular rupture and perifollicular abscess formation. The resulting dermal injury stimulates the wound-healing cascade with enzymatic degradation of collagen fibres and subcutaneous fat that leads to fibrosis and scarring.<sup>94</sup> The severity of scarring is related to both the depth in the dermal pilosebaceous unit where inflammation and wound healing occur and the duration of inflammatory process, as well as an individual's genetic predisposition to scarring. The final result is either a net loss of collagen in the form of atrophic scar types, which are by far the most common,<sup>94–96</sup> or a net gain in the form of hypertrophic scars or keloids.

Atrophic acne scars are commonly classified into ice pick, boxcar and rolling subtypes. Ice pick are the most common and are seen in 60–70% of all patients, the remainder being either boxcar (20–30%) or rolling scars (15–20%).

Subtle differences between each of these subtypes offer a guide to management options. Such differences include scar width, depth and three-dimensional architecture, but they can be difficult to differentiate. Ice pick subtypes are narrow punctiform, very sharply demarcated epithelialised tracks with a wide opening (<2.0 mm) that

tapers as a V shape, to a deeper infundibulum in the deep dermis or subcutaneous fat. In some cases these can branch and interconnect, posing difficulties for surgical excision. Boxcar scars are larger and are characterised by round, oval or angular shaped depressions (1.5–4.0 mm in diameter), which can be shallow (0.1–0.5 mm) or deep ( $\geq 0.5$  mm) with well-defined wide bases with vertical edges and with a cross-sectional U shape. Finally, rolling scars are the result of dermal tethering to the subcutis, which are greater than 4.0–5.0 mm in width and give the appearance of superficial shadowing with an underlying M-shape appearance to otherwise texturally normal skin if seen in isolation. The Goodman and Baron qualitative scoring system is universally accepted<sup>97</sup> is shown in Table 1.

Although acne scars cause significant concern for patients and clinicians alike, there is no standardised treatment protocol or indeed single modality used for all scar types. This is due in part to the variability in both presentation of the scars and also individual response to treatment. Furthermore, there is also variability seen in the resultant scarring that occurs in different patients from similar disease load. However, often the most severe scars result from severe inflammatory nodulocystic acne but may also result from more superficial lesions. Erythema and pigmentation changes represent epidermal damage whereas atrophic, hypertrophic and keloidal scars more frequently indicate dermal damage. Currently, there is no predictive tool to identify patients who are likely to develop acne scars. Despite this, there is general consensus that two key modifiable factors in acne scar formation are pivotal. These are the time delay between onset of effective treatment and the extent and duration of the inflammation. Therefore, in terms of acne scar prophylaxis, early appropriate medical

treatment that is continued for as long as necessary is recommended.

Once atrophic acne scars are established and mature, a number of treatments have been advocated. Many studies used to evaluate these techniques are plagued by lack of adequate control groups, study sample size, objective outcome measures, time to follow-up and a combination of biases. Techniques with supportive level IV evidence include resurfacing manoeuvres that destroy the epidermis and allow for collagenous remodelling. These include dermabrasion or microdermabrasion,<sup>98–100</sup> light or medium-depth chemical peeling with either Jessner solution, 20–35% trichloroacetic (as a spot or generalised peel) or glycolic acids<sup>99,101–103</sup> and the use of various laser technologies.<sup>99,104–106</sup> Ablative lasers used have included both 10,600 nm CO<sub>2</sub> and 2940 nm erbium-doped yttrium-garnet (Er:YAG) lasers which have until recently been regarded as the gold standard.<sup>107–111</sup> While effective in resurfacing, these modalities have been limited by prolonged downtime with oedema, serous discharge and erythema, post-inflammatory hyperpigmentation (PIH), hypopigmentation and the potential risk of worsening atrophic scars with over treatment in the form of further scarring.<sup>112–114</sup> These complications drove the quest for less-invasive laser resurfacing methods with non-ablative lasers. The most widely used of these are the 1320 nm neodymium:yttrium-aluminium-garnet (Nd:YAG) and 1450 nm diode lasers.<sup>115–118</sup> More recently, fractionated photothermolysis through the use of fractional ablative CO<sub>2</sub> laser therapy has been demonstrated to be efficacious in both case reports and non-controlled trials<sup>119–125</sup> with stronger evidence coming from two split-face randomised controlled trials.<sup>126,127</sup>

In terms of surgery, a number of approaches have been proposed. Level V evidence supports scar excision with or without elevation or grafting. Punch biopsy, hair transplant punch or elliptical excision is often performed for ice pick and deep boxcar scars.<sup>94,129</sup> Punch elevation is used for shallow and deep boxcar scars and grafting for sharp walled or very deep ice pick scars.<sup>98,130</sup> Subcision (percutaneously releasing fibrosis) with a tri-bevel bladed needle is supported by level VI evidence and is performed for rolling or depressed scars.<sup>131,132</sup> An alternative to excision, is the correction of the contour deficit seen in the atrophic scars with filler. Level V evidence supports the use of synthetic and biological fillers for superficial, soft, sloping walled scars,<sup>102</sup> but there is a risk of worsening the appearance of scars with underlying fibrotic tethering. Quite often, each of these modalities have been used in combination.<sup>88</sup>

Our unit's approach to the treatment of atrophic acne scarring is to individually direct therapy on a case-by-case basis with the goal to improve scars rather than to deliver a complete cure resulting in a perfect complexion. Treatment depends on the extent and type of scars present and as such, the modality may vary within each facial cosmetic subunit. First, a comprehensive patient history is required which should include all pharmacological acne treatments including recent isotretinoin use and history of any keloid or hypertrophic scarring.

Surgical intervention within six months of the discontinuation of isotretinoin may result in hypertrophic scarring.<sup>133</sup> Therefore, we perform no intervention within a 12-month period of stopping isotretinoin. Furthermore, if there is still active acne inflammation, medical treatment should be optimised in conjunction with primary care and dermatology. Such treatment can be divided into topical and systemic treatments and are often used in combination based on the current European Acne guidelines<sup>134,135</sup> (Table 2).

While medical treatment is being optimised, ice pick and boxcar scars are reconstructed by punch excision, under local anaesthetic or general anaesthesia. Disposable 1.0–3.0 mm punch biopsy instruments are used to excise ice pick scars, to include the shoulders of the scar, full thickness to subcutaneous fat. Boxcar scars are perpendicularly stab excised full thickness with a number 11 blade held backwards, to include the scar walls, following the shape of the scar. Polyfax ointment is used as a dressing. All boxcar and punch excisions 1.5 mm and above are closed with non-absorbable monofilament suture removed at postoperative day 5. Treated scars should be at least 5 mm apart to prevent traction on suturing and prevent adequate wound eversion. Any scars larger than 3.5 mm are excised as an ellipse and closed parallel to relaxed skin tension lines. The goal is to exchange the visibly contoured acne scarring with less visible flat scars. After a test area to access the excisional scarring response, the technique is repeated in stages until all scars have been addressed.

Once acne inflammation and concurrent infection is quiescent, patients with Goodman and Baron grade III or VI scarring, with stretch correctable contour, fractionated photothermolysis for facial resurfacing is performed by our unit. The Lumenis Ultrapulse® fractional ablative CO<sub>2</sub> laser (Lumenis Ltd., Yokneum, Israel) TotalFX® is used. To avoid dyschromia in Fitzpatrick phototypes ≥ V, a simple bleaching mixture of 0.025–0.05% Retin A, 4% hydroquinone and 1% hydrocortisone cream is commenced three to four weeks prior to treatment and continued for

**Table 2.** Summary of recommendations from the current European Acne treatment guideline,<sup>138,139</sup> adapted from Rzany and Nast.<sup>136</sup>

Strength of evidence	Comedonal acne	Mild–moderate papulopustular acne	Severe papulopustular/moderate nodular acne	Severe conglobate acne
High	None	Benzoyl peroxide + adapalene OR clindamycin	Isotretinoin*	Isotretinoin*
Medium	Topical retinoid <sup>†</sup>	Azelaic acid or Benzoyl peroxide or topical retinoid <sup>†</sup> or systemic antibiotic <sup>‡</sup> + adapalene <sup>§</sup>	Systemic antibiotics** + adapalene <sup>§</sup> or systemic antibiotics** + azelaic acid <sup>††</sup> or systemic antibiotics + adapalene + Benzoyl peroxide	Systemic antibiotics** + azelaic acid
Low	Azelaic acid or Benzoyl peroxide	Blue light or oral zinc or topical erythromycin + isotretinoin or topical erythromycin + tretinoin or systemic antibiotic <sup>‡</sup> ,** + Benzoyl peroxide <sup>‡‡</sup> or systemic antibiotic <sup>‡</sup> ,** + azelaic acid <sup>§</sup> or systemic antibiotics <sup>‡</sup> ,** + adapalene + Benzoyl peroxide <sup>§§</sup>	Systemic antibiotics** + Benzoyl peroxide <sup>‡‡</sup>	Systemic antibiotics** + Benzoyl peroxide <sup>‡‡</sup> or systemic antibiotics** + adapalene <sup>§,§§</sup> or systemic antibiotics** + adapalene + Benzoyl peroxide <sup>‡</sup>

\*Limitations can apply that may necessitate the use of a treatment with a lower strength of recommendation as a first-line therapy.

<sup>†</sup>Adapalene to be preferred over tretinoin/isotretinoin.

<sup>‡</sup>In case of more widespread disease/moderate severity, initiation of a systemic treatment can be recommended.

<sup>§</sup>Only studies found on systemic antibiotics + adapalene, Isotretinoin and tretinoin can be considered for combination treatment based on expert opinion. Further alternatives for women include hormonal antiandrogens and topical treatments or systemic antibiotics for severe papulopustular/moderate nodular and severe nodular/conglobate acne.

\*\*Doxycycline and lymecycline.

<sup>††</sup>Indirect evidence from nodular and conglobate acne and expert opinion.

<sup>‡‡</sup>Indirect evidence from a study also including chlorhexidine, recommendation additionally based on expert opinion.

<sup>§§</sup>Indirect evidence from severe papulopustular acne.

two weeks after healing has been completed. For resistant hyperpigmentation, 0.01% Tretinoin and hydroquinone 4%, followed by a Kligmans trio preparation with 5% hydroquinone, 0.01% Fluocinolone and 0.05% Tretinoin is advised.

Up to 80% of the population will have a dormant herpes labialis or herpes zoster infection. For CO<sub>2</sub> laser treatments near the mouth, patients are administered viral prophylaxis to avoid reactivation and antibiotics to avoid post-procedure infection.

The senior author advocates a three-step approach as shown in Schedule 1. At the base of the depression of the atrophic scar, the first pass uses the DeepFX® mode with a very small beam pattern to fit the scar 'hole'. A fluence of 15–20 mJ or up to 30 mJ in very thick and oily skin is used with a density of 10% with a single pulse. The second pass uses the ActiveFX® mode with the

non-sequential array (CoolScan) with a fluence of 50–60 mJ, density of 5–7 and rate of 450 Hz with the hand piece used at 45° to contour the shoulder of the depression with a small-sized beam pattern. An intermediary scrub of this pass is then performed to reveal superficial dermal capillaries in the pink papillary dermis. ActiveFX® mode is then used as a third pass over each entire scarred facial cosmetic subunit with a fluence of 100 mJ, a density of 3 and a rate of 125 Hz. For more aggressive treatments between the second and the third pass, a further pass can be performed using the DeepFX® mode micro scanner on all the areas affected by the acne scars with a fluence of 20–30 mJ, a density of 5–10% with a single pulse. Post procedure, a thin layer of petroleum-based ointment is applied, or if a general anaesthetic has been used EMLA (eutectic mixture of lidocaine 2.5% and prilocaine 2.5%;

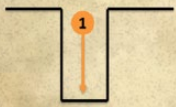


Astra-Zeneca Pharmaceuticals, LP, London, UK) is applied followed by ice packs. Immediately post treatment erythema lasts for a few hours only and the sensation is similar to that of sunburn with a mild serous discharge. Once healed, the treated area will be red for six weeks to six months, but can be covered with makeup. The repeat treatment interval is normally three months, if required. The postoperative care regimen is the same as that used in burns scar treatment.

Scheme 1: Acne technique with the fractional ablative CO<sub>2</sub> laser.

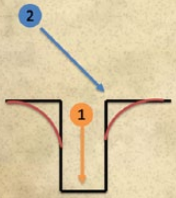
#### A- First pass

- DeepFX down into hole **1** (small size eg 2)
- Energy: 15-20 mJ (or higher till 30 mJ on very thick and oily skin)
- Density: 10%
- Pulse: 1



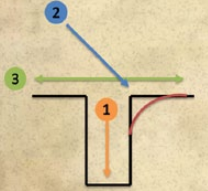
#### B- Second pass

- CPG held at 45° with scrub until scar red
- Small scan size
  - Energy: 60-90mJ
  - Density: 4-5
  - Rate: 450Hz



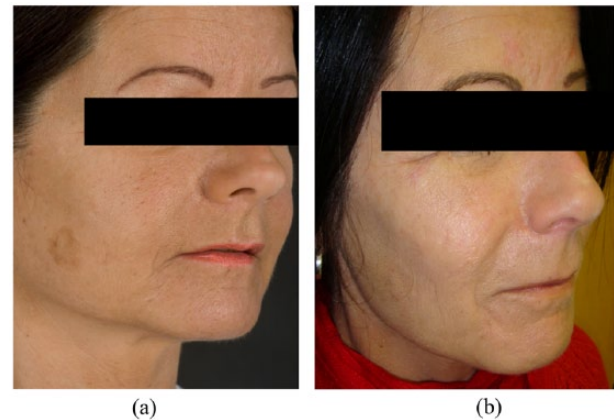
#### C- Third pass

- ActiveFX all over
  - Energy: 100mJ
  - Density: 3
  - Rate: 125Hz
- For Deeper scars – 4<sup>th</sup> DeepFX:
  - Energy: 20-30 mJ
  - Density: 5-10%
  - Pulse: 1



### Acne scarring

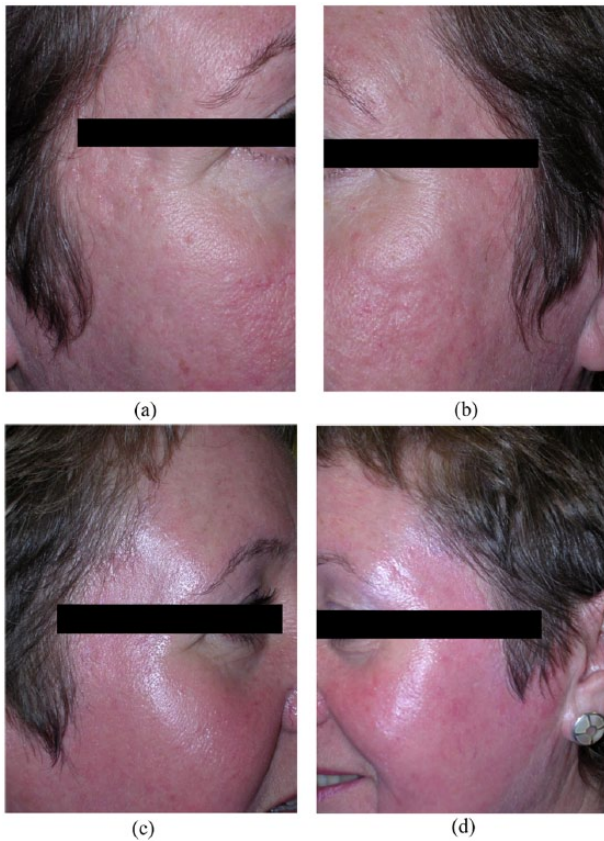
7. A 46-year-old woman, Fitzpatrick type II, with Grade VI Goodman and Baron Acne



**Figure 7.** (a) Pre treatment and (b) post treatment.

Vulgaris scarring presented. She had multiple ice pick, boxcar and cobble stoning scars over bilateral cheeks and forehead. Her inflammation was quiescent with no medication and she was otherwise fit and well. She underwent two cycles of punch excision of the ice pick scars with 1.5, 2.0, 2.5, 3.0 and 4.0 mm punch biopsies. Punches over >2.0 mm were sutured with 5-0 Novafil and removed at postoperative day 5. A total of 110 ice pick scars were excised. At a third stage one year later, ablative CO<sub>2</sub> laser therapy was performed. All elevated scars were treated with multiple passes of Ultrapulse® 2 mm true spot hand piece 175 mJ to flatten to the level of the surrounding epidermis. Fractional DeepFX® mode is then used at each of the scar bases 20 mL, 300 Hz, 2-10-1-10% and over each cosmetic subunit in its entirety at 20 mJ, 2-10-1-5% one pass. Finally, ActiveFX® mode was used over each scar shoulder 80 mJ, 3-5-1%.

8. A 44-year-old woman, Fitzpatrick type II, with Grade VI Goodman and Baron Acne Vulgaris scarring presented. She had multiple cobble stoning scars over bilateral cheeks and temporal regions. Her inflammation was quiescent with no medication and she was otherwise fit and well. She underwent two cycles of fractional ablative CO<sub>2</sub> laser therapy. Fractional DeepFX® mode was used at each of the scar bases 20 mL, 300 Hz, 2-10-1-10% and over each cosmetic subunit in its entirety at 20 mJ, 2-10-1-5% one pass. Finally, ActiveFX® mode was used over each scar shoulder 80 mJ, 3-5-1%.



**Figure 8.** (top) Pre treatment and (bottom) 12 months post last treatment.

### Pigmented and traumatic tattooed scars

Dyschromia within cutaneous scars is a result of abnormal melanogenesis.<sup>137</sup> Eumelanin is a brown-black pigment found in higher ratios in darker skin types and those chronically exposed to ultraviolet radiation, and pheomelanin is a red-brown pigment found in people with fair skin types. Critically, loss of adnexal melanocytic populations and the fundamental melanocytic immunomodulatory, anti-oxidative and anti-inflammatory functions during wound healing is postulated to account for dyspigmentary scarring.<sup>138–140</sup> Most commonly, this is seen as PIH in response to a variety of cutaneous insults.<sup>141</sup>

Prevention of dyschromia is critical. Therapy in tanned and dark skin types is considered on a case-by-case basis with appropriate risk counseling. Patients are warned of a worsening of pigmentation due to the potential hyperactivation of melanocytes and post-laser inflammatory response. Collateral bulk thermal injury is avoided with topical skin cooling; conservative starting treatment parameters, often with a small test

patch, are performed and only when the effects of this test patch are apparent is treatment initiated cautiously with incremental fluence and density adjustments. If dyspigmentation does arise, depigmentation can be achieved medically or mechanically. Chemical depigmentation includes a number of topical agents that work at different stages of melanogenesis to selectively bleach hyperactivated melanocytes. These stages include: (a) prior to melanin synthesis - the regulation of the transcription and activity of tyrosinase, tyrosinase-related protein (TRP)-1 or 2, or peroxidase; (b) during melanin synthesis - by regulating the uptake and distribution of melanosomes in recipient keratinocytes; (c) after melanin synthesis - through melanin and melanosome degradation and processing of pigmented keratinocytes. The senior author advocates the use of tretinoin which acts via retinoid-activated transcription factors and interferes with melanocyte development and melanogenesis. It acts to both stimulate the differentiation of melanocyte precursors, inducing transcription of tyrosinase by protein kinase C activation and microphthalmia transcription factor (MITF) expression, and removes differentiated melanocytes by promoting apoptosis via caspase-3 pathway and bcl-2 down modulation.<sup>142</sup> In addition, it is felt that hydroquinone and azelaic acid derived from *Pityrosporum Ovale*, both of which inhibit tyrosinase activity during melanin synthesis, are useful additions to reduce pigmentation within a scar.

Dermabrasion, cryosurgery, chemical peeling and laser therapy<sup>143–146</sup> as well as conventional surgical excision have been proposed to manage hyperpigmentation. In terms of laser therapy, selective melanin photothermolysis is achieved with a laser that has a wavelength in the absorption spectrum of melanin and sufficient energy levels to target melanosomes.<sup>147,148</sup> Pulse duration should be less than the thermal relaxation of melanin. Wavelengths less than 600 nm penetrate superficially with a lower fluence and thus can be used for epidermal hyperpigmentation, leaving deeper structures intact. Wavelengths longer than 600 nm penetrate more deeply, require a greater fluence and thus can be used to target dermal pigmentation. Energy delivery induces skin whitening due to thermal expansion within the melanosomes leading to local vaporisation and acoustic waves that damage the nucleus and cause melanocytic apoptosis. Melanin that is subsequently released is processed through transepidermal elimination or through phagocytosis by dermal macrophages. Our unit uses short pulsed pigment selective Q-switched alexandrite (755 nm



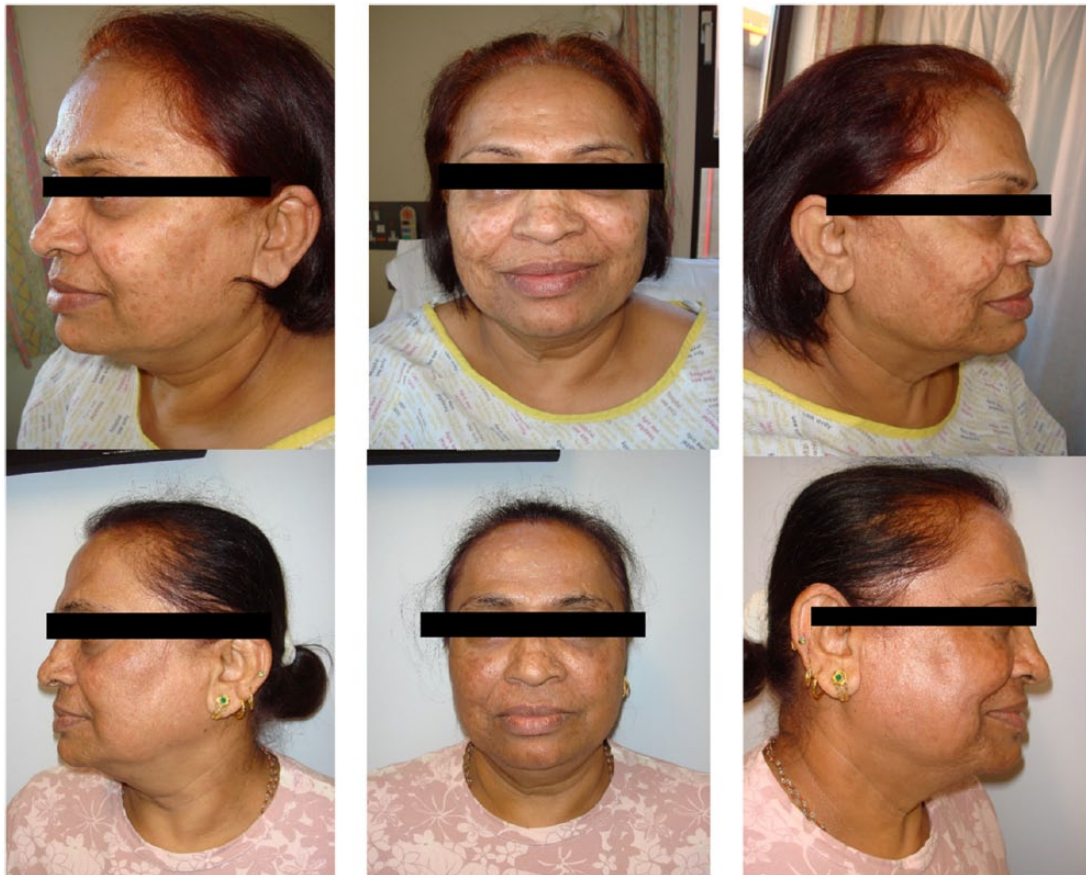wavelength) and Nd:YAG lasers (1064 nm) for dermally pigmented scars. For epidermal pigmentation, the frequency doubled Nd:YAG (532 nm) and the fractional ablative (10,600 nm) CO<sub>2</sub> lasers are used.

Tattooed scars may result from commercial tattooing or traumatic injuries such as road traffic accidents or other encounters with asphalt, explosives or pencil puncture wounds. In addition, they may result from surgical interventions involving inadvertent dermal inoculation. They are most frequently carbon-based and situated in the superficial dermis.<sup>149,150</sup> Conventionally, these lesions have been treated with surgical excision or laser therapy with Q-switched systems.<sup>16</sup> Our preference is to start treatment with either the Q-switched alexandrite (755 nm wavelength) or Nd:YAG lasers (1064 nm). The tattoo ink particles undergo photomechanical fragmentation which reduces both the dark scar colour and prominence as there is a reduction in the inflammatory

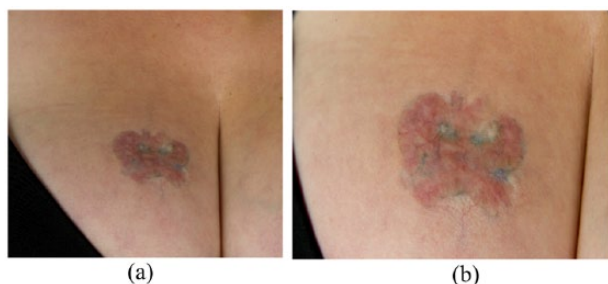and granulomatous reaction driven by the presence of the foreign body.<sup>151</sup> In some resistant cases, formal surgical excision of the tattooed scars or combination therapy is performed.

### Pigmented and tattooed scars

9. A 55-year-old woman, Fitzpatrick type V, presented with hyperpigmented facial scars to her nose, cheeks and chin following smallpox infection as a child. She was otherwise fit and well. She underwent two cycles of fractional ablative CO<sub>2</sub> laser therapy. ActiveFX® mode was used over each scar cosmetic subunit with 175 mJ, 3-9-5 for two passes and edges were blended with 150 mJ, 3-5-1. This was repeated on the nose and anterior cheeks two years later. Pre treatment (top row) and 12 months post last treatment (top row) and 24 months post last treatment with a favourable resolution of the localised scar dyschromia (bottom row).



**Figure 9.** (top) Pre treatment and (bottom) 24 months post last treatment.



**Figure 10.** (a) Pre treatment and (b) after intralesional injection and laser treatment.

10. A 43-year-old woman, Fitzpatrick type II, presented having developed hypertrophic scarring within a tattoo on the right breast following Rejuvi topical tattoo removal treatment. She was otherwise fit and well. She complained of intense pruritus, pain and of its unaesthetic appearance. She underwent two cycles of intralesional injection of 50 mg of 5-FU and 10 mg of Triamcinolone six weeks apart with good response. Thereafter, she underwent laser therapy with the Q-switched Alexandrite (755 nm) system with a fluence of 7.5 Jcm<sup>-2</sup>, 10 Hz with a 2 mm spot. After three sessions over 20 months, the patient was satisfied with its appearance and resolution of symptoms.

### Vascular and contoured scars

Cutaneous scars may exhibit persisting hypervascularity as erythema or telangiectasia. During the proliferative phase of wound healing, VEGF stimulates migratory endothelial cells with subsequent neoangiogenesis. This may persist for many months and can be treated with a variety of vascular lasers and non-coherent intense pulsed light (IPL) sources, all of which work on the principle of selective photothermolysis. The chromophore in a hypervascular scar is haemoglobin which in its erythrocytic oxyhaemoglobin state has a maximum peak absorption of 542 nm ( $\alpha$  peak) and 577 nm ( $\beta$  peak). This can be selectively targeted and damaged with minimal collateral damage to surrounding tissues if the appropriate wavelength of light is used.<sup>152</sup> The photothermolysis induces a selective vascular injury with thrombosis, vessel wall necrosis and perivascular collagen damage with relatively little associated thermal injury in either the epidermis or surrounding dermis.<sup>153</sup>

Vascular lasers include pulsed dye (585 and 595 nm wavelength) and KTP-systems (532 nm),

followed by longer wavelength lasers such as alexandrite lasers (755 nm), diode lasers (800–900 nm) and the Nd:YAG lasers (1064 nm).<sup>154–158</sup> IPL systems differ from lasers in that they simultaneously deliver multiple light wavelengths (500–1200 nm) at different intensities. Lasers in contrast are monochromatic and offer the advantage of high precision and peak power intensity.

1. Components: Gemini laser: Nd-YAG 1064 for deep, KTP 532 for superficial, IPL
2. Special cases: tethered scars, pin cushioned scars, webs.

### Microbes in scar manipulation

Scar quality and scar burden differ significantly with the presence of infective entities. Infection is a well-established contributor to tissue volume loss, inflammation, destruction and organisation.<sup>156</sup> Streptococcal species are associated with skin graft loss and consequently increased scar burden. For this reason, strategies dealing with prophylaxis of infection, early and effective treatment are paramount to reducing the scar burden, especially in the case of extensive disease processes such as large burns. Early diagnostics specific to invasive infection is an area of high clinical demand.<sup>157</sup> Furthermore, an inadvertent source of delayed wound healing may be conventional topical solutions applied to prevent or treat infection.<sup>162</sup>

It is also worth noting that some bacterial products are increasingly being recognised as potential therapeutics in multimodality scar management. Clostridium histolyticum collagenase is now established for the treatment of Dupuytren's disease.<sup>163</sup> Intralesional collagenase followed by compression has been described for ear keloids with some success.<sup>164</sup>

### Conclusion

Scar management presents a significant challenge to the plastic surgeon. This two-part study summarised our Unit's experience in multimodality treatment, with particular reference to the hypertrophic spectrum, acne, pigmented and vascular scarring, based on the senior author's experience spanning nearly 30 years and backed by evidence.

### Declaration of conflicting interests

The authors declared no potential conflicts of interest with respect to the research, authorship, and/or publication of this article.



## Funding

Ernest Azzopardi is supported by the Welsh Assembly Government through a SHIPP Innovation award and the Welsh Clinical Academic Training Scheme.

## References

- Sund B. *New Developments in Wound Care*, vol. 86. London: PJB Publications CBS, 2000.
- Gauglitz GG, Korting HC, Pavicic T, et al. Hypertrophic scarring and keloids: Pathomechanisms and current and emerging treatment strategies. *Mol Med* 2011; 17: 113–125.
- Alster TS and Tanzi EL. Hypertrophic scars and keloids: etiology and management. *Am J Clin Dermatol* 2003; 4: 235–243.
- Juckett G and Hartman-Adams H. Management of keloids and hypertrophic scars. *Am Fam Physician* 2009; 80: 253–260.
- Armour A, Scott PG and Tredget EE. Cellular and molecular pathology of HTS: basis of treatment. *Wound Repair Regen* 2007; 15 (Suppl. 1): S6–17.
- Van der Veen WM, Bloem MC, Ulrich MM, et al. Potential cellular and molecular causes of hypertrophic scar formation. *Burns* 2009; 35: 15–29.
- Arno AI, Gauglitz GG, Barret JP, et al. New molecular medicine-based scar management strategies. *Burns* 2014; 40: 539–551.
- Shih B, Garside E, McGrouther DA, et al. Molecular dissection of abnormal wound healing processes resulting in keloid disease. *Wound Repair Regen* 2010; 18: 139–153.
- Bloemen MC, van der Veer WM, Ulrich MM, et al. Prevention and curative management of hypertrophic scar formation. *Burns* 2009; 35: 463–475.
- Middelkoop E, Monstrey S, Teot L, et al. (eds.). *Scar Management Practical Guidelines*. Brussels: Maca-Cloetens, 2011: 100–109.
- Reiffel RS. Prevention of hypertrophic scars by long-term paper tape application. *Plast Reconstr Surg* 1995; 96: 1715–1718.
- Gurtner GC, Dauskardt RH, Wong VW, et al. Improving cutaneous scar formation by controlling the mechanical environment: large animal and phase I studies. *Ann Surg* 2011; 254: 217–225.
- Gassner HG, Sherris DA and Otle CC. Treatment of facial wounds with botulinum toxin A improves cosmetic outcome in primates. *Plas Reconstr Surg* 2000; 105: 1948–1953.
- Suetake T, Sasai S, Zhen YX, et al. Functional analyses of the stratum corneum in scars. Sequential studies after injury and comparison among keloids, hypertrophic scars, and atrophic scars. *Arch Dermatol* 1996; 132: 1453
- Mustoe TA. Evolution of silicone therapy and mechanism of action in scar management. *Aesthetic Plast Surg* 2008; 32: 82–92.
- Engrav LH, Heimbach DM, Rivara FP, et al. 12-Year within wound study of the effectiveness of custom pressure garment therapy. *Burns* 2010; 36: 975–983.
- Shin TM and Bordeaux JS. The role of massage in scar management: a literature review. *Dermatol Surg* 2012; 38: 414–423.
- Rques C. Massage applied to scars. *Wound Repair Regen* 2002; 10: 126–128.
- Field T, Peck M, Hernandez-Rief M, et al. Postburn itching: pain, and psychological symptoms are reduced with massage therapy. *J Burn Care Rehabil* 2000; 21: 189–193.
- Patino O, Novick C, Merlo A, et al. Massage in hypertrophic scars. *J Burn Care Rehabil* 1999; 20: 268–271.
- Atiyeh BS. Nonsurgical management of hypertrophic scars: evidence-based therapies, standard practices, and emerging methods. *Aesth Plast Surg* 2007; 31: 468–492.
- Anzarut A, Olson J, Singh P, et al. The effectiveness of pressure garment therapy for the prevention of abnormal scarring after burn injury: a meta-analysis. *J Plast Reconstr Aesthet Surg* 2009; 62: 77–84.
- Macintyre L and Baird M. Pressure garments for use in the treatment of hypertrophic scars: a review of the problems associated with their use. *Burns* 2006; 32: 10–15.
- Reno F, Grazianetti P and Cannas M. Effects of mechanical compression on hypertrophic scars: prostaglandin E2 release. *Burns* 2001; 27: 215–218.
- Mustoe TA. Evolution of silicone therapy and mechanism of action in scar management. *Aesthetic Plast Surg* 2008; 32: 82–92.
- Baisch A and Riedel F. Hyperplastische Narben un Keloide. *HNO* 2006; 54: 981–994.
- Steinstraesser L, Flak E, Witte B, et al. Pressure garment therapy alone and in combination with silicone for the prevention of hypertrophic scarring: randomized controlled trial with intra-individual comparison. *Plast Reconstr Surg* 2011; 128: 306e–313e.
- Atkinson JA, McKenna KT, Barnett AG, et al. Randomized: controlled trial to determine the efficacy of paper tape in preventing hypertrophic scar formation in surgical incision that traverse Langer's skin tension lines. *Plast Reconstr Surg* 2005; 116: 1648–1656.
- O'Brien L and Jones DJ. Silicone gel sheeting for preventing and treating hypertrophic and keloid scars. *Cochrane Database Syst Rev* 2013; 9: CD003826.
- Rockwell WB, Cohen IK and Ehrlich HP. Keloids and hypertrophic scars: a comprehensive review. *Plast Reconstr Surg* 1989; 84: 827–837.
- Mustoe TA, Cooter RD, Gold MH, et al. International Advisory Panel on Scar Management. International clinical recommendations on scar management. *Plast Reconstr Surg* 2002; 110: 560–571.
- Urioste SS, Arndt KA and Dover JS. Keloids and hypertrophic scars: review and treatment strategies. *Semin Cutan Med Surg* 1999; 18: 159–171.
- Ogawa R, Akaishi S, Huang C, et al. Clinical applications of basic research that shows reducing skin tension could prevent and treat abnormal scarring: the importance of fascial/subcutaneous tensile reduction sutures and flap surgery for keloid and hypertrophic scar reconstruction. *J Nippon Med Sch* 2011; 78: 68–76.
- Lee KK, Mehrany K and Swanson NA. Surgical revision. *Dermatol Clin* 2005; 23: 141–150.
- Engrav LH, Gottlieb JR, Millard SP, et al. A comparison of intramarginal and extramarginal excision of hypertrophic burn scars. *Plast Reconstr Surg* 1988; 81: 40–45.
- Guix B, Henriquez I and Andres A. Treatment of keloids by high-dose-rate brachytherapy: a seven-year study. *Int J Radiat Oncol Biol Phys* 2001; 50: 167–172.
- Yossi S, Krhili S, Mesgouez-Nebout N, et al. Adjuvant treatment of keloid scars: electrons or brachytherapy? *Cancer Radiother* 2013; 17: 21–25.
- Ogawa R, Yoshitatsu S, Yoshida K, et al. Is radiation therapy for keloids acceptable? The risk of radiation-induced carcinogenesis. *Plast Reconstr Surg* 2009; 124: 1196–1201.
- Ogawa R, Mitsuhashi K, Kyakusoku H, et al. Postoperative electron-beam irradiation therapy for keloids and hypertrophic scars: retrospective study of 147 cases followed for more than 18 months. *Plast Reconstr Surg* 2003; 111: 547–553.
- Poston J. The use of silicone gel sheeting in the management of hypertrophic and keloid scars. *J Wound Care* 2000; 9: 10–16.
- Mustoe, Thomas A., et al. International clinical recommendations on scar management. *Plastic and reconstructive surgery* 110.2 (2002): 560-571.

42. Ogawa R. The most current algorithms for the treatment and prevention of hypertrophic scars and keloids. *Plast Reconstr Surg* 2010; 125: 557–568.
43. Burd A and Huang L. Keloid. In Best practice monographs in the clinical evidence series. London: BMJ Publishing, 2012.
44. Wang XQ, Liu YK, Qing C, et al. A review of the effectiveness of antimetabolic drug injections for hypertrophic scars and keloids. *Ann Plast Surg* 2009; 63: 688–692.
45. Niessen FB, Spauwen PHM, Schalkwijk J, et al. On the nature of hypertrophic scars and keloids: a review. *Plast Reconstr Surg* 1999; 104: 1435–1458.
46. Wong, Thian-Sze, et al. “The Efficacy of Triamcinolone Acetonide in Keloid Treatment: A Systematic Review and Meta-analysis.” *Frontiers in Medicine* 3 (2016).
47. Sproat JE, Dalcin A, Weitauer N, et al. Hypertrophic sternal scars: silicone gel sheeting versus kenalog injection treatment. *Plast Reconstr Surg* 1992; 90: 988–992.
48. Gressel MG, Parrish RK 2nd and Folberg R. 5-fluorouracil and glaucoma filtering surgery: I. An animal model. *Ophthalmology* 1984; 91: 378–383.
49. Heuer DK, Parrish RK 2nd, Gressel MG, et al. 5-fluorouracil and glaucoma filtering surgery. II. A pilot study. *Ophthalmology* 1984; 91: 384–394.
50. Fitzpatrick RE. Treatment of inflamed hypertrophic scars using intralesional 5-FU. *Dermatol Surg* 1999; 25: 224–232.
51. Apikian M and Goodman G. Intralesional 5-fluorouracil in the treatment of keloid scars. *Australas J Dermatol* 2004; 45: 140–143.
52. Darougheh A, Asilian A and Shariati F. Intralesional triamcinolone or in combination with 5-fluorouracil for treatment of keloid and hypertrophic scars. *Clin Exp Dermatol* 2007; 34: 219–223.
53. Gupta S and Kalra A. Efficacy and safety of intralesional 5-fluorouracil in the treatment of keloids. *Dermatology* 2002; 204: 130–132.
54. Kontochristopoulos G, Stefanaki C, Panagiotopoulos A, et al. Intralesional 5-fluorouracil in the treatment of keloids: an open clinical and histopathologic study. *J Am Acad Dermatol* 2005; 52: 474–479.
55. Uppal RS, Khan U, Kakar S, et al. The effects of a single dose of 5-fluorouracil on keloid scars: a clinical trial of timed wound irrigation after extralesional excision. *Plast Reconstr Surg* 2001; 108: 1218–1224.
56. Davison SP, Dayan JH, Clemens MW, et al. Efficacy of intralesional 5-fluorouracil and triamcinolone in the treatment of keloids. *Aesthet Surg J* 2009; 29: 40–46.
57. Huang L, Cai Y, Lung I, et al. A study of the combination of triamcinolone and 5-fluorouracil in modulating keloid fibroblasts in vitro. *JPRAS* 2013; 66: e251–259.
58. Liu W, Wu X, Gao Z, et al. Remodelling of keloid tissue into normal-looking skin. *J Plast Reconstr Aesthet Surg* 2008; 61: 1553–1554.
59. Reish RG and Eriksson E. Scar treatments: preclinical and clinical studies. *J Am Coll Surg* 2008; 206: 719–730.
60. Muir IF. On the nature of keloid and hypertrophic scars. *Br J Plast Surg* 1990; 43: 61–69.
61. Leventhal D, Furr M and Reiter D. Treatment of keloids and hypertrophic scars: a meta-analysis and review of the literature. *Arch Facial Plast Surg* 2006; 8: 362–368.
62. Syed F, Ahmadi E, Iqbal SA, et al. Fibroblasts from the growing margin of keloid scars produce higher levels of collagen I and III compared with intralesional and extralesional sites: clinical implications for lesional site-directed therapy. *Br J Dermatol* 2011; 164: 83–96.
63. Gailloud-Mathieu M, Raffoul W and Egloff DV. Citrices hypertrophiques et cheloides: quelles options therapeutiques aujourd'hui? *Revue Medicale de la Suisse Romande* 1999; 119: 721–728.
64. Shepherd J and Dawber RPR. Historical and scientific basis of cryosurgery. *Clin Exp Dermatol* 1982; 7: 321–328.
65. van Leeuwen, Michiel CE, et al. “Intralesional cryotherapy for treatment of keloid scars: a prospective study.” *Plastic and reconstructive surgery* 135.2 (2015): 580-589.
66. Ruscioni L, Rossi G and Bono R. Use of cryotherapy in the treatment of keloids. *J Dermatol Surg Oncol* 1993; 19: 529–534.
67. Zouboulis CC, Blume U, Buttner P, et al. Outcomes of cryosurgery in keloids and hypertrophic scars: a prospective consecutive trial of case series. *Arch Dermatol* 1993; 129: 1146–1151.
68. Har-Shai, Yaron, and Christos C. Zouboulis. “Intralesional cryotherapy for the treatment of keloid scars: a prospective study.” *Plastic and reconstructive surgery* 136.3 (2015): 397e-398e.
69. Har-Shai Y, Mettanes I, Genin O, et al. Keloid histopathology after intralesional cryoneedle treatment. *J Eur Acad Dermatol Venereol* 2011; 25: 1027–1036.
70. Weshahy AH. Intralesional cryosurgery. A new technique using cryoneedles. *J Dermatol Surg* 1993; 19: 123–126.
71. Har-Shai Y, Sabo E, Rohde E, et al. Intralesional cryosurgery markedly enhances the involution of recalcitrant auricular keloids – A new clinical approach supported by experimental studies. *Wound Repair Regen* 2006; 14: 18–27.
72. Har-Shai Y, Amar M and Sabo E. Intralesional cryotherapy for enhancing the involution of hypertrophic scars and keloids. *Plastic Reconstr Surgery* 2003; 111: 1841–1852.
73. Har-Shai Y, Brown W, Labbe’ D, et al. Intralesional cryosurgery for the treatment of hypertrophic scars and keloids following aesthetic surgery. *Int J Lower Extrem Wounds* 2008; 7: 169–175.
74. Har-Shai Y, Brown W, Pallua N, et al. Intralesional cryosurgery for the treatment of hypertrophic scars and keloids. *Plast Reconstr Surg* 2010; 126: 1798–1800.
75. Har-Shai Y. Intralesional cryosurgery for enhancing the involution of hypertrophic scars and keloids. A new effective technology based on experimental and clinical data. *Journal of Wound Technology* 2012; 15: 8–9.
76. Har-Shai Y and Har-Shai L. Intralesional cryosurgery for the treatment of upper lip keloid following deep chemical peeling. *Eur J Plastic Surgery* 2014; 37: 679–682.
77. Har-Shai Y and Weidman MJ. The treatment of keloids and hypertrophic scars through intralesional cryotherapy. *Kosmetische Medizin* 2012; 33: 48–52 (In German).
78. Zouboulis CC, Rosenberger AD, Forster T, et al. Modification of a device and its application for intralesional cryosurgery of old recalcitrant keloids. *Arch Dermatol* 2004; 140: 1293–1294.
79. Gupta S and Kumar B. Intralesional cryosurgery using lumbar puncture and/or hypodermic needles for large, bulky, recalcitrant keloids. *Int J Dermatol* 2001; 40: 349–353.
80. Mirmovich O, Gil T, Goldin I, et al. Pain evaluation and control during and following the treatment of hypertrophic scars and keloids by contact and intralesional cryosurgery—a preliminary study. *J Eur Acad Dermatol Venereol* 2012; 26: 440–447.
81. Har-Shai Y, Dujovny E, Rohde E, et al. Effect of skin surface temperature on skin pigmentation during contact and intralesional cryosurgery of keloids. *J Eur Acad Dermatol Venereol* 2007; 21: 191–198.
82. Berman, Brian, Andrea Maderal, and Brian Raphael. “Keloids and hypertrophic scars: pathophysiology, classification, and treatment.” *Dermatologic Surgery* 43 (2017): S3-S18.
83. Niessen FB, Spauwen PHM, Schalkwijk J, et al. On the nature of hypertrophic scars and keloids: a review. *Plast Reconstr Surg* 1999; 104: 1435–1458.

84. Levy DS, Salter MM and Roth RE. Postoperative irradiation in the prevention of keloids. *AJR Am J Roentgenol* 1976; 50: 457.
85. Ghodsi SZ, Orawa H and Zouboulis CC. Prevalence, severity, and severity risk factors of acne in high school pupils: a community-based study. *J Invest Dermatol* 2009; 129: 2136–2141.
86. Capitanio B, Sinagra JL, Bordignon V, et al. Underestimated clinical features of postadolescent acne. *J Am Acad Dermatol* 2010; 63: 782–788.
87. Williams C and Layton AM. Persistent acne in women: implications for the patient and for therapy. *Am J Clin Dermatol* 2006; 7: 281–290.
88. Jacob CI, Dover JS and Kaminer MS. Acne scarring: a classification system and review of treatment options. *J Am Acad Dermatol* 2001; 45: 109–117.
89. Stathakis V, Kilkenny M and Marks R. Descriptive epidemiology of acne vulgaris in the community. *Australas J Dermatol* 1997; 38: 115–123.
90. Goulden V, Stables GI and Cunliffe WJ. Prevalence of facial acne in adults. *J Am Acad Dermatol* 1999; 41: 577–580.
91. Jemec GBE, Linneberg A, Nielsen NH, et al. Have oral contraceptives reduced the prevalence of acne? A population-based study of acne vulgaris and tobacco smoking and oral contraceptives. *Dermatology* 2002; 204: 179–184.
92. Koo JY and Smith LL. Psychologic aspects of acne. *Pediatr Dermatol* 1991; 8: 185–188.
93. Kurokawa I, Danby FW, Ju Q, et al. New developments in our understanding of acne pathogenesis and treatment. *Exp Dermatol* 2009; 18: 821–832.
94. Fife D. Practical evaluation and management of atrophic acne scars: tips for the general dermatologist. *J Clin Aesthet Dermatol* 2011; 4: 50–57.
95. Fife D and Zachary CB. Combining techniques for treating acne scars. *Curr Dermatol Rep* 2012; 1: 82–88.
96. Thiboutot D and Gollnick H. New insights into the management of acne: an update from the Global Alliance to Improve Outcomes in Acne Group. *J Am Acad Dermatol* 2009; 60: S1–S50.
97. Goodman GJ and Baron JA. Postacne scarring: a qualitative global scarring grading system. *Dermatol Surg* 2006; 32: 1458–1466.
98. Goodman G. Post-acne scarring: a review. *J Cosmet Laser Ther* 2003; 5: 77–95.
99. Fulton JE Jr and Silverton K. Resurfacing the acne-scarred face. *Dermatol Surg* 1999; 25: 353–359.
100. Bhalla M and Thami GP. Microdermabrasion: reappraisal and brief review of literature. *Dermatol Surg* 2006; 32: 809–814.
101. Al-Waiz MM and Al-Sharqi AI. Medium-depth chemical peels in the treatment of acne scars in dark-skinned individuals. *Dermatol Surg* 2002; 28: 383–387.
102. Goodman GJ. Management of post-acne scarring: what are the options for treatment? *Am J Clin Dermatol* 2000; 1: 3–17.
103. Lee JB, Chung WG, Kwahck H, et al. Focal treatment of acne scars with trichloroacetic acid: chemical reconstruction of skin scars method. *Dermatol Surg* 2002; 28: 1017–1021.
104. Rogachefsky AS, Hussain M and Goldberg DJ. Atrophic and a mixed pattern of acne scars improved with a 1320-nm Nd:YAG laser. *Dermatol Surg* 2003; 29: 904–908.
105. Jeong JT, Park JH and Kye YC. Resurfacing of pitted facial acne scars using Er:Yag laser with ablation and coagulation mode. *Aesthetic Plast Surg* 2003; 27: 130–134.
106. Sawcer D, Lee HR and Lowe NJ. Lasers and adjunctive treatment for facial scars: a review. *J Cutan Laser Ther* 1999; 1: 77–85.
107. Alster TS and Zaulyanov-Scanlon L. Laser scar revision: A review. *Dermatol Surg* 2007; 33: 131–140.
108. Tanzi EL and Alster TS. Treatment of atrophic facial scars with a dual-mode Er:YAG laser. *Dermatol Surg* 2002; 28: 551–555.
109. Alster TS and West TB. Resurfacing of atrophic facial acne scars with a high-energy, pulsed carbon dioxide laser. *Dermatol Surg* 1996; 22: 151–154.
110. Alster TS, Nanni CA and Williams CM. Comparison of four carbon dioxide resurfacing lasers. A clinical and histopathologic evaluation. *Dermatol Surg* 1999; 25: 153–158.
111. Alster TS. Clinical and histologic evaluation of six erbium: YAG lasers for cutaneous resurfacing. *Lasers Surg Med* 1999; 24: 87–92.
112. Khatri KA, Ross V, Grevelink JM, et al. Comparison of erbium:YAG and carbon dioxide lasers in resurfacing of facial rhytides. *Arch Dermatol* 1999; 135: 391–397.
113. Ross EV, Miller C, Meehan KP, et al. One-pass CO<sub>2</sub> versus multiple-pass Er:YAG laser resurfacing in the treatment of rhytides: A comparison side-by-side study of pulsed CO<sub>2</sub> and Er:YAG lasers. *Dermatol Surg* 2001; 27: 709–715.
114. Alster TS and Lupton JR. Prevention and treatment of side effects and complications of cutaneous laser resurfacing. *Plast Reconstr Surg* 2002; 109: 308–316.
115. Tanzi EL and Alster TS. Comparison of a 1450-nm diode laser and a 1320-nm Nd:YAG laser in the treatment of atrophic facial scars: a prospective clinical and histologic study. *Dermatol Surg* 2004; 30: 152–157.
116. Chan HH, Lam LK, Wong DS, et al. Use of 1,320 nm Nd:YAG laser for wrinkle reduction and the treatment of atrophic acne scarring in Asians. *Lasers Surg Med* 2004; 34: 98–103.
117. Sadick NS and Schecter AK. A preliminary study of utilization of the 1320-nm Nd:YAG laser for the treatment of acne scarring. *Dermatol Surg* 2004; 30: 995–1000.
118. Bellew SG, Lee C, Weiss MA, et al. Improvement of atrophic acne scars with a 1,320 nm Nd:YAG laser: retrospective study. *Dermatol Surg* 2005; 31: 1218–1222.
119. Chapas AM, Brightman L, Sukal S, et al. Successful treatment of acneiform scarring with CO<sub>2</sub> ablative fractional resurfacing. *Lasers Surg Med* 2008; 40: 381–386.
120. Walgrave SE, Ortiz AE, MacFalls HT, et al. Evaluation of a novel fractional resurfacing device for treatment of acne scarring. *Lasers Surg Med* 2009; 41: 122–127.
121. Cho SB, Lee SJ, Kang JM, et al. The efficacy and safety of 10,600-nm carbon dioxide fractional laser for acne scars in Asian patients. *Dermatol Surg* 2009; 35: 1955–1961.
122. Chan NP, Ho SG, Yeung CK, et al. Fractional ablative carbon dioxide laser resurfacing for skin rejuvenation and acne scars in Asians. *Lasers Surg Med* 2010; 42: 615–623.
123. Wang YS, Tay YK and Kwok C. Fractional ablative carbon dioxide laser in the treatment of atrophic acne scarring in Asian patients: A pilot study. *J Cosmet Laser Ther* 2010; 12: 61–64.
124. Cho SB, Lee SJ, Cho S, et al. Non-ablative 1,550-nm erbium-glass and ablative 10,600-nm carbon dioxide fractional lasers for acne scars: A randomized split-face study with blinded response evaluation. *Acad Dermatol Venereol* 2010; 24: 921–925.
125. Jung JY, Lee JH, Ryu DJ, et al. Lower-fluence, higher-density versus higher-fluence, lower-density treatment with a 10,600-nm carbon dioxide fractional laser system: A split-face, evaluator-blinded study. *Dermatol Surg* 2010; 36: 2022–2029.
126. Hedelund L, Haak CS, Togsverd-Bo K, et al. Fractional CO<sub>2</sub> laser resurfacing for atrophic acne scars: a randomized controlled trial with blinded response evaluation. *Lasers in Surgery and Medicine* 2012; 44: 447–452.
127. Bjørn M, Stausbøl-Grøn B, Olesen AB, et al. Treatment of acne scars with fractional CO<sub>2</sub> laser at 1-month versus 3-month intervals: an intra-individual randomized control trial. *Lasers in Surgery and Medicine* 2014; 46: 89–93.



128. Bhatia N, David CV, Hazany S, et al. Acne scarring. In: Zeichner JA (ed.). *Acneiform Eruptions in Dermatology: A Differential Diagnosis*. New York: Springer; 2014: 237–243.
129. Sardana K, Manjhi M, Garg VK, et al. Which type of atrophic acne scar (ice-pick, boxcar, or rolling) responds to nonablative fractional laser therapy? *Dermatol Surg* 2014; 40: 288–300.
130. Goodman GJ. Postacne scarring: a review of its pathophysiology and treatment. *Dermatol Surg* 2000; 26: 857–871.
131. Batra RS. Surgical techniques for scar revision. *Skin Therapy Lett* 2005; 10: 4–7.
132. Alam M, Omura N and Kaminer MS. Subcision for acne scarring: technique and outcomes in 40 patients. *Dermatol Surg* 2005; 31: 310–317.
133. Roenigk HH Jr. Dermabrasion: state of the art. *J Dermatol Surg Oncol* 1985; 11: 306–314.
134. Nast A, Dreno B, Bettoli V, et al. European evidence-based (S3) guidelines for the treatment of acne. *J Eur Acad Dermatol Venereol* 2012; 26 (Suppl. 1): 1–29.
135. Nast A, Rosumeck S, Sammain A, et al. Methods report on the development of the European S3 guidelines for the treatment of acne. *J Eur Acad Dermatol Venereol* 2012; 26 (Suppl. 1): e1–e41.
136. Razny B and Nast A. Acne treatment in the field: how guidelines and other sources can be included in daily practice. *JEADV* 2013; 27 (Suppl. 2): 2–5.
137. Tyack ZF, Pegg S and Ziviani J. Postburn dyspigmentation: its assessment, management, and relationship to scarring—a review of the literature. *J Burn Care Rehabil* 1997; 18: 435–440.
138. Plonka PM, Passeron T, Brenner M, et al. What are melanocytes really doing all day long? *Exp Dermatol* 2009; 18: 799–819.
139. Randhawa M, Huff T, Valencia JC, et al. Evidence for the ectopic synthesis of melanin in human adipose tissue. *Faseb J* 2009; 23: 835–843.
140. Breathnach AS and Chadwick S. Melanocytes in early regenerated human epidermis. *J Invest Dermatol* 1960; 35: 245–251.
141. Coelho SG, Zhou Y, Bushar HF, et al. Long-lasting pigmentation of human skin, a new look at an overlooked response to UV. *Pigment Cell Melanoma Res* 2009; 22: 238–241.
142. Watabe H, Soma Y, Ito M, et al. All-transretinoic acid induces differentiation and apoptosis of murine melanocyte precursors with induction of the microphthalmia-associated transcription factor. *J Inv Dermatol* 2002; 118: 35–42.
143. Li YT and Yang KC. Comparison of the frequency-doubled Q-switched Nd:YAG laser and 35% trichloroacetic acid for the treatment of face lentiginosities. *Dermatol Surg* 1999; 25: 202–204.
144. Kunachak S, Leelaudomlapi P and Wongwaisayawan S. Dermabrasion: a curative treatment for melasma. *Aesthetic Plast Surg* 2001; 25: 114–117.
145. Stratigos AJ, Dover JS and Arndt KD. Laser treatment of pigmented lesions-2000. *Arch Dermatol* 2000; 136: 915–921.
146. Anderson RR. Laser in dermatology—a critical update. *J Dermatol* 2000; 27: 700–705.
147. Anderson RR and Parish JA. Selective photothermolysis. Precise microsurgery by selective absorption of pulsed radiation. *Science* 1983; 220: 524–527.
148. Brazzini B, Hautmann G, Ghersetich I, et al. Laser tissue interaction in epidermal pigmented lesions. *J Eur Acad Dermatol Venereol* 2001; 15: 388–391.
149. Bowes LE, Nouri K, Berman B, et al. Treatment of pigmented hypertrophic scars with the 585 nm pulsed dye laser and the 532 nm frequency-doubled Nd:YAG laser in the Q-switched and variable pulse modes: a comparative study. *Dermatol Surg* 2002; 28: 714–719.
150. Kauvar ANB and Hruza GJ. *Principles and Practices in Cutaneous Laser Surgery*. Boca Raton, FL: Taylor & Francis, 2005.
151. Kuperman-Beade M, Levine VJ and Ashinoff R. Laser removal of tattoos. *Am J Clin Dermatol* 2001; 2: 21–25.
152. Altshuler GB, Anderson RR, Manstein D, et al. Smirnov MZ. Extended theory of selective photothermolysis. *Lasers Surg Med* 2001; 29: 416–432.
153. Reddy KK, Brauer JA, Idriss MH, et al. Treatment of port-wine stains with a short pulse width 532-nm Nd:YAG laser. *J Drugs Dermatol* 2013; 12: 66–71.
154. Mordon S, Brisot D and Fournier N. Using a ‘non uniform pulse sequence’ can improve selective coagulation with a Nd:YAG laser (1.06 microm) thanks to Met-hemoglobin absorption: a clinical study on blue leg veins. *Lasers Surg Med* 2003; 32: 160–170.
155. Black JF, Wade N and Barton JK. Mechanistic comparison of blood undergoing laser photocoagulation at 532 and 1,064 nm. *Lasers Surg Med* 2005; 36: 55–65.
156. Rose AE and Goldberg DJ. Successful treatment of facial telangiectasias using amicropulse 1,064-nm neodymium-doped yttrium aluminum garnet laser. *Dermatol Surg* 2013; 39: 1062–1066.
157. Glaich AS, Goldberg LH, Dai T, et al. Fractional photothermolysis for the treatment of telangiectatic matting: a case report. *J Cosmet Laser Ther* 2007; 9: 101–103.
158. Bencini PL, Tourlaki A, De Giorgi V, et al. Laser use for cutaneous vascular alterations of cosmetic interest. *Dermatol Ther* 2012; 25: 340–351.
159. Borges da Costa J, Boixeda P, Moreno C, et al. Treatment of resistant port-wine stains with a pulsed dual wavelength 595 and 1064 nm laser: a histochemical evaluation of the vessel wall destruction and selectivity. *Photomed Laser Surg* 2009; 27: 599–605.
160. Azzopardi E and Boyce DE. Clostridium histolyticum collagenase in the treatment of Dupuytren’s contracture. *Br J Hosp Med (Lond)* 2012; 73: 432–436.
161. Azzopardi EA, Azzopardi E, Camillieri L, et al. Gram negative wound infection in hospitalised adult burn patients—systematic review and meta-analysis. *PLoS One* 2014; 9: e95042
162. Bae-Harboe YSC, Harboe-Schmidt JE, Graber E, et al. Collagenase followed by compression for the treatment of earlobe keloids. *Dermatol Surg* 2014; 40: 519–524.
163. Heyneman A, Hoeksema H, Vandekerckhove D, et al. The role of silver sulphadiazine in the conservative treatment of partial thickness burn wounds: A systematic review. *Burns* 2016; 42: 1377–1386.
164. Marshall CD, Hu MS, Leavitt T, et al. Cutaneous scarring: Basic science, current treatments, and future directions. *Advances in Wound Care* 2016. DOI: 10.1089/wound.2016.0696

### How to cite this article

McGoldrick RB, Theodorakopoulou E, Azzopardi E, et al. Lasers and ancillary treatments for scar management Part 2: Keloid, hypertrophic, pigmented and acne scars. *Scars, Burns & Healing*, Volume 3, 2017. DOI: 10.1177/205951311689805.