

A resistant case of Kawasaki Disease

Shirley Mulvaney, Cecil Vella, Victor Grech

Abstract

Kawasaki disease (KD) is an acute febrile illness of childhood of unknown origin which may cause coronary arteritis and death. The Maltese incidence has been calculated at 3.2/100,000 population \leq 4 years of age, similar to that reported in European communities and far lower than that reported in Asian countries. The use of steroids in this condition remains contentious. We report a resistant case of KD who required two doses of pulsed steroids in addition to standard treatment with aspirin and immunoglobulin.

Introduction

Kawasaki disease (KD), formerly known as mucocutaneous lymph node syndrome, is an acute febrile illness of childhood of unknown origin. The underlying pathology is an arteritis involving small and medium sized arteries. Diagnosis is based on clinical criteria which include conjunctivitis, oral manifestations, polymorphous rash, and swelling of the peripheries which is followed by peeling. The most severe complication is coronary arteritis, which may lead to aneurysm formation, and the eventual formation of coronary artery strictures. The frequency of this complication has decreased from 25% to 2-3% with the availability of treatment which involves high dose, intravenous γ -globulin and high dose aspirin.

Key words

Anti-inflammatory agents, mucocutaneous lymph node syndrome

We report our first immunoglobulin resistant case of KD who required treatment with two doses of pulsed steroids. We also extend the results of an earlier study which had shown the annual number of cases of KD.¹ With regard to incidence, the catchment area for this study was Malta. Cases of KD were identified from computerised ward admission records for the period 1992 to date.

Case summary

Our patient presented with a 4 day history of fever up to 104°F, nonpurulent conjunctivitis and a maculopapular rash on the thighs, shins and extensor surfaces of the forearms. He was being followed up regularly at Children's Outpatients for a small ventricular septal defect. By the following day, the rash had spread to the face. The suspicion of sepsis due to a high white blood cell count led to commencement of ceftriaxone (Table 2). 24 hours later, he also developed mucositis and swelling of the hands and feet with palmar erythema, and a diagnosis of Kawasaki disease was made. He was administered intravenous immunoglobulin (IVIG) 2g/kg, started on high dose aspirin (25mg/kg/6h) and the fever dropped to 99-100°F. Despite normal renal function tests, he became oliguric with normal urinalysis and microscopy, was catheterised and intravenous fluids were increased. No effusions were noted on echocardiography and the coronary arteries were normal (Figure 1). On day 8 of the acute illness, the rash on the lower limbs started to fade and the ceftriaxone was stopped. Several boluses of fluids and frusemide were administered over the next few days as the oliguria persisted. He still had low grade fever (99-100°F), but aspirin had to be stopped as he started passing melaena. A second course of high dose immunoglobulins was administered together with regular ranitidine and frusemide. A repeat echocardiogram only showed good cardiac function, a small pericardial effusion and trivial mitral and tricuspid regurgitation that had not been noted before. He became hypoalbuminaemic and was given 20% albumin (LFTs otherwise normal) and was restarted on antibiotics (cefotaxime) in view of the persistently high WBC count. A transfusion was also given due to a dropping haemoglobin (Table 1, day 9). He subsequently developed gross abdominal distension, and a greenish nasogastric aspirate due to a combination of ascites and ileus secondary to hypokalaemia. A surgical review advised the addition of omeprazole as the stools had remained dark and tarry in consistency. Due to the concern with regard to the possibility of endocarditis, on day 12, the antibiotics were changed to teicoplanin and meropenem

Shirley Mulvaney MD
Paediatric Department, Mater Dei Hospital, Msida, Malta

Cecil Vella MD, FRCP(UK)
Paediatric Department, Mater Dei Hospital, Msida, Malta

Victor Grech* PhD, FRCPCH
Paediatric Department, Mater Dei Hospital, Msida, Malta
Email: victor.e.grech@gov.mt

* corresponding author

and an albumin infusion was repeated. Some peeling of the extremities was noted over the next few days. As the patient's general condition improved, the rash faded, and the mucositis cleared, aspirin was restarted, and the antibiotics were stopped as cultures had remained negative throughout. On day 24, diffuse coronary artery dilatation (Figure 1) concomitant with

a rise in temperature prompted the administration of pulsed methylprednisolone 400mg daily. He remained afebrile over the next 3 days and was discharged on aspirin 300mg 6 hourly (100mg/kg/day) and omeprazole 20mg daily. After 4 days, he was readmitted in view of increasing inflammatory indices and persistent low grade fever (day 38 in Table 1). Methylprednisolone 400mg daily, was readministered for 3 days and he was again discharged on aspirin and omeprazole. Since discharge he has remained afebrile and well. His blood count and c-reactive protein levels were monitored at each visit as shown in Table 1. Coronary dilatation slowly improved on subsequent echos and no aneurysms were seen. Interestingly, the platelet count only rose and persisted above $400 \times 10^9/l$ by day 20, after the second dose of steroids.

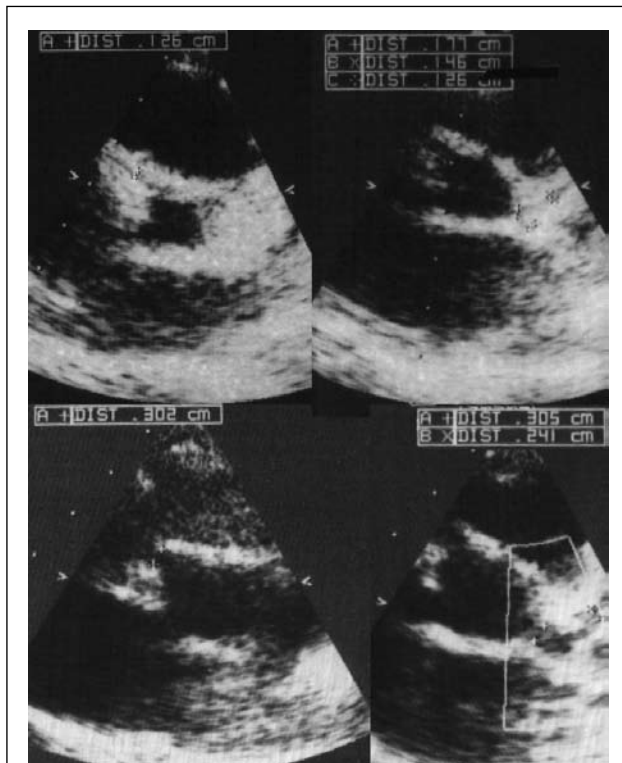


Figure 1: Top left; normal right coronary artery. Top right; normal left coronary artery. Bottom right; dilated right coronary artery origin. Bottom left; dilated left coronary artery and branches (left anterior descending indicated by cursor)

Kawasaki disease in Malta

The annual number of patients with KD is shown in Table 2. The incidence has remained static since our previous study.¹

Discussion

The rate of KD in Malta remains similar to rates reported for European populations,^{2,3} and much less than that reported in purely Asiatic populations (Table 2).⁴

Accelerated matrix breakdown caused by the increased activity of matrix metalloproteinases (MMPs) and/or the quantitative imbalance between MMP and tissue inhibitor of MMP (TIMP) have been implicated in the destruction of the coronary arterial wall and the resultant coronary arterial lesions in Kawasaki disease.⁵ The blockade of plasminogen activators prevents the formation of aneurysms and arterial rupture by inhibiting MMP activation. High dose intravenous gammaglobulins (IVIG) combined with oral aspirin, to reduce inflammation in the coronary arterial wall, has become the standard treatment during the acute phase of Kawasaki

Table 1: Patient indices

Day	Hb (g/dl)	WBC ($\times 10^9/l$)	Plt ($\times 10^9/l$)	CRP (u/l)
4	11	19.4	284	
7	9.5	33.3	190	304
9	8.1	33	151	186
11	12.4	26.3	129	147
13	11.3	23.1	212	116
17	10.1	11.8	356	70
20	9.8	7.03	489	45
23	8.4	7.98	477	162
28	7.5	12.7	448	179
31	12.2	9.72	491	31
38	12.4	14.7	417	187
46	12.4	25.5	583	67
52	12.3	17.6	610	6

Table 2: Annual cases of KD extended from a previous publication (rate 3.2/100,000 population < 5 years of age for the period 1992-1997)¹

Year	Annual cases
1992	2
1993	0
1994	2
1995	1
1996	1
1997	4
1998	1
1999	0
2000	0
2001	0
2002	1
2003	3
2004	0
2005	4
2006	1

disease. The efficacy of IVIG in preventing coronary artery lesions may therefore be related to protection against arterial wall destruction via reduction of cytokine induced MMP stimulation. Some Kawasaki disease patients that have been administered high dose IVIG continue to suffer from coronary artery aneurysms. Corticosteroids have been proposed as an effective treatment for Kawasaki disease and several recent studies suggest that corticosteroid therapy can be effective.⁵ The potent anti-inflammatory effects of steroids are well established, and these include the suppression of inflammatory cytokines and a direct inhibitory effect on MMP activation. Steroids are now primarily used to treat Kawasaki disease patients who are unresponsive to IVIG therapy. However, studies have shown that initial treatment with combined high dose IVIG and corticosteroids is more effective in the prevention of coronary artery lesions than the use of IVIG or steroids on their own but more detailed studies with double blind placebo control are required.⁶

Our current practice is to administer high dose IVIG at diagnosis and introduce pulsed methylprednisolone only if the disease remains active. The earlier introduction of steroids may be justified if poor prognostic factors for coronary artery lesions, such as excessive fluid retention or hypoalbuminaemia are present.⁷

Acknowledgements

The Paediatric Department consultants for lending their patients to this study.

References

1. Grech V. Incidence and outcome of Kawasaki disease in Malta. *Adv Exp Med Biol.* 1999;455:69-72
2. Dhillon R, Newton L, Rudd P T, Hall S M. Management of Kawasaki disease in the British Isles. *Arch Dis Child* 1993;69:631-6.
3. Smith PK, Goldwater PN. Kawasaki disease in Adelaide: a review. *J Paediatr Child Health* 1993;29:126-31
4. Yanagawa H, Yashiro M, Nakamura Y, Kawasaki T, Kato H. Epidemiologic pictures of Kawasaki disease in Japan: from the nationwide incidence survey in 1991 and 1992. *Pediatrics* 1995;95:475-9
5. Senzaki H, Masutani S, Kobayashi J, Kobayashi T, Nakano H, Nagasaka H, Sasaki N, Asano H, Kyo S, Yokote Y. Circulating matrix metalloproteinases and their inhibitors in patients with Kawasaki disease. *Circulation* 2001; 104:860-3
6. Inoue Y, Okada Y, Shinohara M, Kobayashi T, Kobayashi T, Tomomasa T, Takeuchi K, Morikawa A. A multicenter prospective randomized trial of corticosteroids in primary therapy for Kawasaki disease: clinical course and coronary artery outcome. *J. Paediatr.* 2006;149:336-41.
7. Honkanen VE, McCrindle BW, Laxer RM, Feldman BM, Schneider R, Silverman ED. Clinical relevance of the risk factors for coronary artery inflammation in Kawasaki disease. *Pediatr Cardiol.* 2003;24:122-6.

Corinthia Group Prize in Paediatrics, 2007

For the first time since its inception, the Corinthia Group Prize in Paediatrics was awarded jointly to Dr Rodianne Vassallo and Dr Daniel Cauchi, who both obtained the same top aggregate mark over the combined examinations in Paediatrics in the fourth and final year of the undergraduate course. As always, competition for the Corinthia Group Prize was as stiff as ever, with ten candidates vying for the honour and a tie for the top spot! Whilst offering our congratulations to Dr Rodianne Vassallo and Dr Daniel Cauchi, we would also like to congratulate all those undergraduates (now doctors) who performed admirably during the undergraduate course in Paediatrics. In the accompanying photograph, Dr Vassallo and Dr Cauchi are seen receiving their (shared) cheque for Lm50 each from Professor Simon Attard Montalto, Head of Paediatrics at the Medical School. Finally, the Academic Department of Paediatrics and Medical School remain indebted and are extremely grateful to the Corinthia Group for their ongoing support.

Professor Simon Attard Montalto

