

# Proximal femoral focal deficiency - a case report

Marthese Ellul, Marcelle Chircop, Charles Grixti, Victor Grech

## Abstract

Proximal Femoral Focal Deficiency (PFFD) is a rare and complex congenital anomaly (1:50,000-200,000 population) that results in varying degrees of femoral hypoplasia with limb shortening and pelvic abnormalities. It may be present bilaterally in association with other malformations/deficiencies of the lower limbs, and the upper limbs may also be involved. Other anomalies may also be present such as cleft palate, congenital heart defects, and spinal anomalies. The aetiology is unknown. We present a case of PFFD who was born locally.

## Key words

Lower limb, Neonate, Femur/\*abnormalities,  
Fibula/\*abnormalities

**Marthese Ellul** MD MRCPCH  
Department of Paediatrics, Mater Dei Hospital, Msida, Malta

**Marcelle Chircop** MD MRCOG  
Department of Obstetrics and Gynaecology,  
Mater Dei Hospital, Msida, Malta

**Charles Grixti** MD FRCS  
Department of Orthopaedics, Mater Dei Hospital, Msida, Malta

**Victor Grech\*** PhD FRCPCH  
Department of Paediatrics, Mater Dei Hospital, Msida, Malta  
Email: victor.e.grech@gov.mt

\* corresponding author

## Introduction

Proximal Femoral Focal Deficiency (PFFD) is a rare (1:50,000-200,000 population) but complex congenital anomaly that is characterised by varying degrees of femoral hypoplasia resulting in limb shortening and pelvic abnormalities. It may be bilateral in 15% of cases and may be associated with absent fibula (50-80%), short tibia and fibula, patellar absence/hypoplasia/malposition, limb malrotation, and proximal joint instability and absence of anterior and posterior cruciate ligaments.<sup>1</sup> Contralateral upper and lower limb deformities may also be present.<sup>2</sup> The precise aetiology is still unknown and a genetic cause has not been isolated. Other anomalies may also be present in up to 70%, such as cleft palate, clubfoot, congenital heart defects, and spinal anomalies.<sup>3</sup> We present a case of PFFD who was born locally.

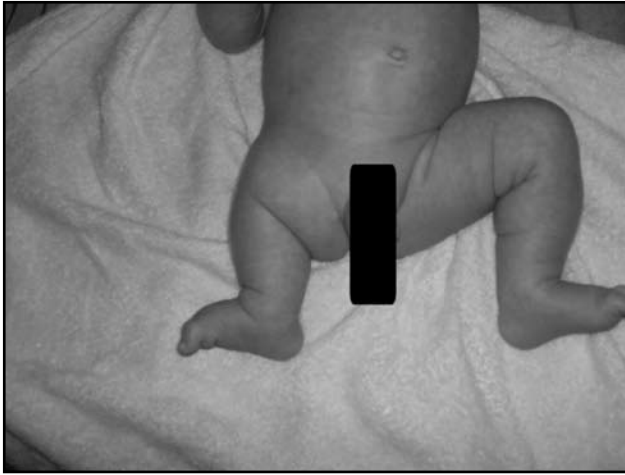
### *Table 1: Aitken classification (in increasing order of severity)*

**Class A:** Shortened femur present proximally, ending at or slightly above the level of the acetabulum. The femoral head is often absent but later ossifies; femoral head presence is indicated by a well-developed acetabulum. Additionally, there is a subtrochanteric defect, which eventually ossifies and thereby establishes bony continuity. After ossification, there is usually a residual subtrochanteric varus deformity.

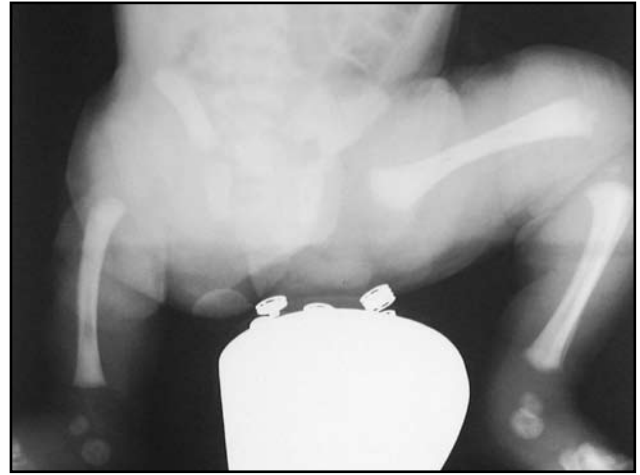**Class B:** A more severe defect or absence of the proximal femur. This defect does not heal spontaneously. At skeletal maturity, there is no connection between the femoral head and proximal femur; the end of the proximal femur is above the acetabulum. The femoral head, although present, may have delayed ossification, and there is often a bony tuft on the proximal end of the shaft.

**Class C:** Absent femoral head that does not ossify and a markedly dysplastic acetabulum. The femoral shaft is shorter than in a person with class B.

**Class D:** Severely shortened femoral shaft, which often has only an irregularly ossified tuft of bone proximal to the distal femoral epiphysis. No acetabulum is present with a flatlateral pelvic wall.



**Figure 1:** Physical appearance of lower limbs. Note short right lower limb and absent thigh (consent to use this photograph was given by the parents)



**Figure 2:** X-ray of both lower limbs – femur, fibula and acetabulum are absent on the right side (consent to use this photograph was given by the parents)

## Patient

Our patient (male) was born by emergency caesarean section for malrotation and poor progress in the second stage after medical induction at term. The pregnancy had been uneventful. The mother is English, the father is Maltese, and the child was born locally in a private hospital.

The parents are healthy and unrelated and there was no family history of this condition or any other congenital anomaly. The family had three other children with no problems and there had not been any miscarriages.

At birth, he was noted to have a short right lower limb with an absent thigh (Figure 1). An X-ray of both lower limbs showed absent femur, fibula and acetabulum on the right side.

No other congenital anomalies were noted and a renal ultrasound was normal. The child is now 11 months old. An echocardiogram was not performed as cardiovascular examination was entirely normal.

Our patient has been reviewed by both local orthopaedic as well as by visiting orthopaedic colleagues. He is being followed up at St. Luke's Prosthetics and Physiotherapy Departments. He has also been referred for genetic evaluation.

## Discussion

PFFD is a rare disorder. Several classification systems exist and the most widely used is the Aitken classification which is based on the radiographic appearance described by Aitken (Table 1).<sup>3</sup> Our patient cannot, as yet, be assigned to any Aitkens category since late ossification may occur whereby portions of femur may become apparent. The absence of the acetabulum in our patient denotes the most severe form of PFFD.<sup>4</sup> Our patient was fortunate in that this appears to have been a single isolated anomaly.

The aim of management is to provide proximal stability, optimal function and cosmetic appearance. The two most important considerations are predicted femoral length at maturity and pelvic-femoral stability. Assessment with computed tomography and/or magnetic resonance imaging is invaluable.

If the foot is at the level of the opposite knee, the foot may be amputated and the knee fused to provide an above knee stump to allow an above knee prosthesis to be fitted.<sup>5</sup> An alternative procedure is a rotationplasty where the foot and ankle are rotated 180° and the knee fused so that the foot faces backwards and acts as a new knee.<sup>6</sup> Treatment options may therefore include combination/s of: amputation, prostheses, joint fusion, osteotomies, epiphysiodesis, knee arthrodesis, hip stabilisation or arthrodesis and rotationplasty.<sup>7</sup>

## References

1. Koman LA, Meyer LC, Warren FH. Proximal femoral focal deficiency: a 50-year experience. *Dev Med Child Neurol* 1982;24:344-55.
2. Oppenheim WL, Setoguchi Y, Fowler E: Overview and comparison of Syme's amputation and knee fusion with the van Nes rotationplasty procedure in proximal femoral focal deficiency. In: Herring JA, Birch J, eds. *The Child With a Limb Deficiency*. Chicago, Ill: American Academy of Orthopaedic Surgeons; 1998.
3. Aitken GT: Proximal femoral focal deficiency-Definition, classification, and management. In: Aitken GT, ed. *Proximal Femoral Focal Deficiency. A Congenital Anomaly*. Washington, DC: National Academy of Sciences; 1969.
4. Fixsen JA, Lloyd-Roberts GC. The natural history and early treatment of proximal femoral dysplasia. *J Bone Joint Surg Br.* 1974;56:86-95.
5. Panting AL, Williams PF. Proximal femoral focal deficiency. *J Bone Joint Surg Br.* 1978;60:46-52.
6. Torode IP, Gillespie R. Rotationplasty of the lower limb for congenital defects of the femur. *J Bone Joint Surg Br.* 1983;65:569-73.
7. Bryant DD, Epps CH. Proximal femoral focal deficiency: evaluation and management. *Orthopedics.* 1991;14:775-84.