

Case of benign familial fleck retina with foveal involvement

James Vassallo

Abstract

Retinal dystrophies constitute a diagnostic challenge in view of their rarity, wide range, and overlapping features, usually requiring multimodal investigations to establish the diagnosis. It is important to assess the inheritance pattern, and provide the patient with prognostic information. Treatment is limited.

Keywords

retinal dystrophy; flecks; drusen

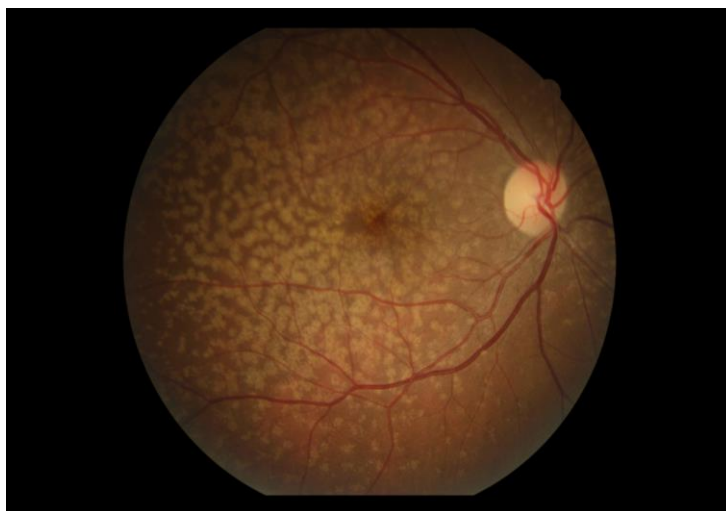Case

A 37-year-old female presented for a routine eye test. She was asymptomatic. Fundoscopy revealed bilateral symmetrical widespread subretinal deposits, as shown in the colour photos.

Discussion

A provisional diagnosis of benign familial fleck retina was made based on the characteristic appearance described elsewhere.¹ It is usually autosomal recessive, but autosomal dominant inheritance has also been reported. It is the only case known in Malta, however retinal screening of family members of proband was not carried out. The patient will be observed and no deterioration in vision is expected. The fovea is usually not involved in this condition, so this case is atypical. Despite the presence of foveal flecks, the patient was asymptomatic, typical of this condition. Retinal flecks may be misdiagnosed as drusen or exudates, and are found in several fundus dystrophies. Pattern recognition is the primary method of establishing a diagnosis of benign familial fleck retina.

Figure 1: Fleck retina, right eye



James Vassallo MD(Melit) MRCSEd FICO FEBO
Department of Ophthalmology
Mater Dei Hospital
Msida, Malta
jamesvassallo2000@yahoo.com

Figure : Fleck retina, left eye

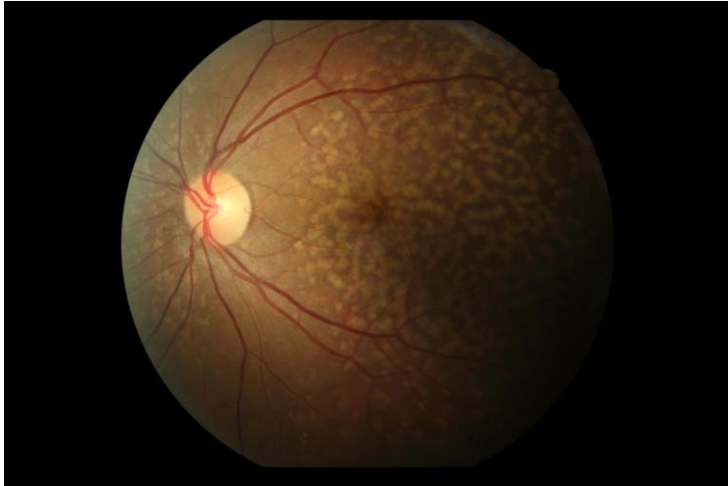


Image description

A multitude of yellowish, granular, ill-defined subretinal lesions in a mosaic pattern, mostly confluent, and some separated by normal retina. The macula, including the fovea, was heavily involved, but the peripapillary area was relatively clear. The extramacular area to the periphery was also similarly involved, but the lesions were smaller and more widely separated. The retinal vessels and disc are normal.

Reference

1. Dorairaj SK, Murthy KR, Ritch R. Four-generation familial benign fleck retina. *Retin Cases Brief Rep* 2007;1(1):25-6